

# Surgical correction of HIV-associated facial lipoatrophy

Giovanni Guaraldi<sup>a</sup>, Joan Fontdevila<sup>b</sup>, Lise H. Christensen<sup>c</sup>,  
Gabriella Orlando<sup>a</sup>, Chiara Stentarelli<sup>a</sup>, Federica Carli<sup>a</sup>, Stefano Zona<sup>a</sup>,  
Giorgio de Santis<sup>d</sup>, Antonio Pedone<sup>d</sup>, Domenico De Fazio<sup>e</sup>,  
Pierluigi Bonucci<sup>e</sup> and Esteban Martínez<sup>f</sup>

*AIDS* 2011, **25**:1–12

**Keywords:** autologous fat transfer, facial fillers, HIV, lipodystrophy

## Introduction

Lipodystrophy was first described in HIV-1-infected patients in 1998 [1–5]. The main clinical feature is subcutaneous fat loss or lipoatrophy of the face, limbs, and buttocks [6,7]. Patients can also experience fat accumulation within the abdomen, neck or breasts [8,9]. The pathogenesis of lipoatrophy appears to be multifactorial. Contributing factors are CD4<sup>+</sup> lymphocyte cell count, HIV clinical stage, race, sex, exercise level, age at start of antiretroviral therapy [8], and the rapidity of its onset may depend on the individual total fat mass. The driving force behind lipoatrophy is undoubtedly the cumulative exposure to thymidine analogue drugs. These drugs, in particular stavudine and to a lesser extent zidovudine, block mitochondrial DNA polymerase function producing apoptosis of fat cells [9,10]. Earlier detection and treatment of HIV infection [11], as well as the use of antiretroviral drugs with less deleterious effects on body fat, make it reasonable to hypothesize a decrease in prevalence of lipodystrophy in the coming years.

Facial lipoatrophy is characterized by loss of the buccal and/or temporal fat pads, leading to facial skeletonization with concave cheeks, prominent naso-labial folds, periorbital hollowing, and visible facial musculature [10–12]. A volume deficit of this type will alter the youthful, healthy, convex curves of the face into aged, pathologic, concave contours [13–16]. Facial fat depletion may occur within the first year of treatment [15] and the risk increases along with cumulative exposure to highly active antiretroviral therapy (HAART) [16]. Patients with HIV-associated lipoatrophy have a fairly rapid and localized loss of facial soft tissue, unlike the slower loss of facial fullness associated with aging [17].

Facial lipoatrophy is a stigmatizing feature of HIV-related lipodystrophy. Facial appearance is usually perceived as a manifestation of health and cannot be hidden behind clothes. Studies have demonstrated the negative psychosocial impact and impairment of quality of life (QoL) from lipodystrophy due to erosion of self-image and self-esteem, demoralization and depression, problems in social and

<sup>a</sup>Clinica delle Malattie Infettive, Università degli Studi di Modena e Reggio Emilia, Italy, <sup>b</sup>Department of Plastic Surgery, Hospital Clinic, University of Barcelona, Barcelona, Spain, <sup>c</sup>Department of Pathology, Bispebjerg Hospital, University of Copenhagen, Denmark, <sup>d</sup>Department of Plastic and Reconstructive Surgery, University of Modena and Reggio Emilia, <sup>e</sup>Plastic Surgery Unit, Casa Di Cura Salus Hospital, Reggio Emilia, Italy, and <sup>f</sup>Hospital Clínic-Institut d'Investigacions Biomèdiques August Pi i Sunyer, University of Barcelona, Barcelona, Spain.

Correspondence to Esteban Martínez, MD, PhD, Infectious Diseases Unit, Hospital Clínic-Institut d'Investigacions Biomèdiques August Pi i Sunyer, University of Barcelona, C/Villarroel 170, 08036 Barcelona, Spain.

Tel: +34 93 2275430; fax: +34 93 4514438; e-mail: esteban@fundsoriano.es

Received: 10 May 2010; revised: 3 August 2010; accepted: 3 August 2010.

DOI:10.1097/QAD.0b013e32833f1463

sexual relations [18,19]. In addition, lipodystrophy often may result in HIV disclosure [20]. Several studies have demonstrated the potential for reversibility of lipoatrophy by switching from stavudine or zidovudine to thymidine analogue-sparing regimens, although improvement in subcutaneous fat is slow and incomplete [21–23]. Initial promising data on the beneficial effects of certain drugs such as rosiglitazone, pioglitazone, pravastatin or uridine on lipoatrophy has been either inconclusive or unconfirmed [24–27]. For this reason, as in other acquired or congenital lipoatrophies, plastic surgery seems to be up to now the mainstay of treatment, offering either lipofilling, or biodegradable, or nonbiodegradable filler injections.

Search strategies and selected criteria

Data to review were identified by protocolized searches through MEDLINE, references from relevant articles, and abstract books of the first nine International Workshops on Adverse Drug Reactions and Lipodystrophy. Search terms were ‘Lipodystrophy’, ‘HIV’, and ‘Plastic surgery’. Studies reported in the English language only were included. We aimed at providing an updated comprehensive knowledge of the surgical approaches for reconstruction of HIV-related facial lipoatrophy. We specifically looked for criteria to qualify for surgery, to choose among surgical interventions, to identify clinical outcomes and to manage side effects.

Indications for surgical treatment of HIV-related face lipoatrophy

Severity of facial lipoatrophy

The severity of facial lipoatrophy is probably the most important issue to qualify for surgical treatment. However, assessment of HIV facial lipoatrophy is not easy. Objective methods have occasionally been used, but the measurement of facial fat is challenging [28,29]. Up to now there is neither a standardized available tool to measure facial pad thickness, nor clear facial reference points that could be of use in the clinical setting.

In an attempt to standardize lipoatrophy severity, a photo comparison grading scale has been proposed and utilized. James *et al.* [30] suggested to consider a four-stage severity scale. Degree 1 is defined as a minimal fat wasting of the cheeks only, and slight enhancement of the naso-labial folds. Degree 2 refers to moderate fat wasting of the cheeks, obvious enhancement of the naso-labial folds and appearance of ‘naso-labial bands’. Degree 3 is characterized by moderate fat wasting of cheeks and temporal regions with prominent naso-labial folds (naso-labial bands), and in degree 4 there is severe fat wasting and hollowing of cheeks, temporal, and periocular regions, resulting in visible facial bony prominences [31]. Fontdevila *et al.* [32], more recently, suggested to consider a three-degree severity scale only (mild, moderate, severe) and was able to validate a new photo comparison grading scale with objective volume measurement obtained by CT scan. Fig.1 represents

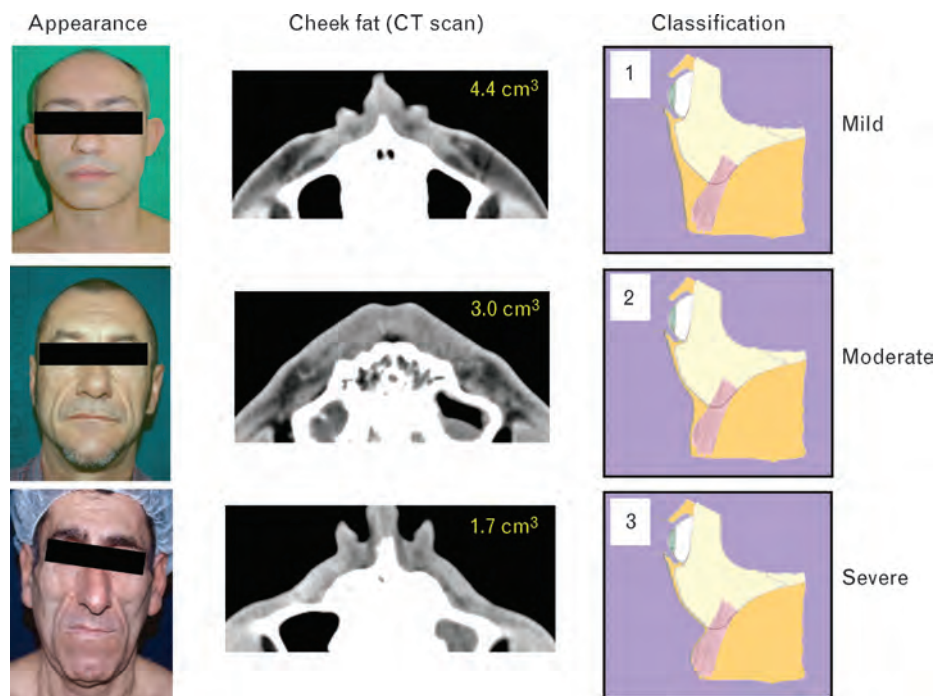


Fig. 1. Classification of facial lipoatrophy in clinical stages and picture comparison.

these pictures currently used both at Modena Metabolic Clinic (Italy) and at Barcelona Hospital Clinic (Spain) as comparison references. The main difference between these classification system concerns degree 1 alias 'mild facial lipoatrophy'. Patients with malar flattening, but no noticeable nasolabial folds are included in this category. Plastic surgery is usually offered to patients presenting with moderate to severe facial lipoatrophy.

### Psychological repercussion of facial lipoatrophy

Psychological repercussion is another characteristic that may qualify for surgical treatment. Psychometric inclusion criteria take into account psychological consequences of lipodystrophy by examining body image perception by means of the 'Assessment of Body Change and Distress Questionnaire' especially conceived to analyse perceptions, attitudes, feelings, emotions, actions and satisfactions concerning body appearance and functioning [33,34]. This is an extremely useful tool, as some patients with a mild to moderate face lipoatrophy may experience a deep detriment of body image perception, whereas others with a more severe form could have the psychological resources to better cope with this condition.

Treatment efficacy has predominantly been assessed subjectively by clinicians and patients, either by non-standardized photography, or radiological tools, mainly ultrasound and CT scan [35–38]. It should be stressed that the buccal fat pad has a minor role in the facial appearance and does not have a concrete area in superficial anatomy. For this reason, ultrasound evaluation of the cheek is a controversial end point in plastic facial reconstruction surgery.

### Surgical treatment of HIV-related face lipoatrophy

Surgical interventions can be summarized as follows: autologous fat transplantation (AFT) [39–41], and injections of biodegradable [hyaluronic acid, poly-L-lactic acid (PLA), hydroxyapatites] [42–45] or nonbiodegradable [silicon, polymethylmethacrylate (PMMA), polyacrylamide hydrogel, polyalkylimide] gel fillers [46].

The classification refers exclusively to the biological proprieties of these materials. They do not necessary correlate with the durability of the aesthetic results. For example PLA and hydroxyapatites consist of particles that are slowly degraded, but the bulk of the tissue fibrosis, they provoke, is permanent.

It is possible to use in time sequence in the same anatomical site different re-absorbable materials considering their biodegradability, whereas it is absolutely advised not to mix in the same site absorbable and nonabsorbable fillers.

### Autologous fat transplantation

Autologous fat transplantation allows the harvesting of a small intact lump (parcel) of fatty tissue that can be processed to remove nonviable components and simultaneously avoid mechanical trauma or exposure. Utilizing strict sterile procedures the fat is injected through a cannula to ensure intimate tissue incorporation and thus limit migration. There are different phases of AFT as initially reported by Coleman [39–41].

- (1) Harvesting: A clinical or ultrasound evaluation is made to define the presence of subcutaneous fat in the abdomen, pubis, male breast, thoracic–dorsal and dorso-cervical region. Local or general anaesthesia or deep sedation is provided after discussing with the patient and considering his clinical conditions. Ringer's lactate with 1 : 1 000 000 of epinephrine and 50 ml of 2% lidocaine every 1 l of Ringer's lactate, if local anaesthesia is used, is infiltrated bluntly through a stab incision prior to harvesting. The harvesting device is a 10-ml disposable Luer-lock syringe attached to a two-holed blunt cannula. The entry portal of the cannula is just large enough to allow passage of fatty tissue parcels of a size that will pass through the lumen of the tip of the Luer-lock syringe. To limit the vacuum to a minimum negative pressure, suction is hand-applied by slowly withdrawing the plunger of the 10-ml syringe in a gradual manner. The harvesting relies on the curetting action as well as the suctioning.
- (2) Transfer and purification: The harvesting cannula is disconnected from the Luerlock and replaced by a cap. The plunger of the syringe is then removed, and the capped 10-ml syringe is placed into a sterilization sleeve in a sterilized central rotor of a centrifuge, which spins it at about 3000 r.p.m. for 3 or 4 min. The aspirated subcutaneous material separates into three basic layers: a top layer composed primarily of oil from ruptured fat cells; a bottom layer, composed almost entirely of blood, lidocaine and Ringer's lactate; and a middle layer of primarily usable fat tissue. The top oily layer is decanted, the dense lower layer is drained, and the remaining fat parcels are transferred in to a 1-ml Luer-lock syringe.
- (3) Placement: The fat placement is performed using an 18-gauge cannula with an ejection aperture close to the closed distal end. The ejection portal is just large enough to allow passage of the fat parcels. The intact parcels are forced out of the ejection aperture by depressing the plunger on the infiltrating syringe. The size, shape and internal finish of the cannula are designed to reduce clogging and trauma to the parcels of fatty tissue. The distal end is blunt in order to reduce the risk of haematoma, nerve damage, and perforation of non-targeted tissue. The cannula initially creates tunnels inside the recipient tissue, and as it is withdrawn, the plunger of the syringe is depressed in a controlled manner so that a minuscule amount of the refined tissue (usually less than 1/8 of a millilitre) is placed evenly over the length of the tunnel. Only a minimal positive

pressure is ever placed on the plunger of the infiltration syringe. For 8–12 h postoperatively, cold compresses or ice packs are applied continuously on the infiltrated sites. The patient can be discharged after 2 h if local anaesthesia with sedation has been used and after 8–24 h following general anaesthesia. Apart from the operative risks the only identified complication described has been the facial fat hypertrophy at the same time of recurrence of fat hypertrophy in the harvest site [47].

### Biodegradable synthetic gel fillers

Biodegradable synthetically produced gel fillers used in HIV-related facial lipoatrophy include cross-linked hyaluronic acid, PLA and hydroxyapatite gel [42–45].

#### *Hyaluronic acid gel*

Native hyaluronic acid is a normal polysaccharide component of mammalian soft tissues. The type of hyaluronic acid, which in gel form is injected into human tissues, has been molecularly modified – mainly by increasing cross-linkage to delay degradation – and this product, a homogenous polymer hydrogel, is FDA-approved for the treatment of wrinkles. Enzymatic degradation is delayed and the filling effect increased, both thanks to the cross-linking. Hyaluronic acid gel was compared to bovine collagen in a study funded by one of the company manufacturing and proved to be more durable than the bovine collagen and very well tolerated [43]. Hyaluronic acid has been used successfully to treat HIV facial lipoatrophy, but large volumes of material are necessary to achieve an optimal result, and the filling effect lasts for a maximum of 6–8 months. In general cosmetic practice, the benefits are expected to last for 6–12 months, but in a small series of five individuals with HIV lipoatrophy, who were given 5–6 ml into the malar area, sustained aesthetic benefits were only reported through 6 months [43,45].

#### *Poly-L-lactic acid gel*

Poly-L-lactic acid is present in normal tissues so that it can be degradable by tissue enzymes. The gel consists of microspheres of poly-lactic acid dissolved in, and a quickly degradable carrier gel, and it has been approved by the FDA for use in HIV-associated lipoatrophy [42]. The microparticles trigger the host tissue to produce a foreign body response, which eventually stimulates the connective and fat tissue fibroblasts to produce collagen, and this de-novo collagen production is responsible for the filling effect. The gel is usually injected subcutaneously in multiple sessions, resulting in different stages of the structural tissue augmentation. When injected in dermis thickening it gives a harder consistency of the skin.

As can be seen with other filling materials, results in the temporal area are generally less satisfactory than those in the buccal area. The material is immunologically inert. Inflammatory responses are very infrequent, but granulomas occur and are the most common complication due

to this filler. PLA is gradually degraded and excreted over 2–3 years during which time a gradual tissue augmentation is taking place. Treatment is generally given in 3–5 sessions with intervals of 2–6 weeks, leading to a gradual change in facial appearance. As experience with PLA has increased various strategies have been suggested to reduce the risk of and avoid the potential complications (granulomas) associated. These include: higher volume dilution (8–12 ml/vial), fewer vials used at each session, injections placed in the subcutaneous plane without any going into the dermis, adequate time between injection sessions (at least 6 weeks), postinjection patient massage [48].

#### *Calcium hydroxyapatite gel*

Preparations based on calcium hydroxyapatite (CaHA) microspheres suspended in carboxymethylcellulose gel were originally FDA-approved for vocal cord injections and for use as bone cement in a range of orthopaedic surgery approaches. This product, however, has also been widely used for treatment of wrinkles and lip augmentation. Like poly-lactic acid CaHA is a component of normal tissues (bone tissue), and the product is bio-absorbable over several years. In one study on 30 HIV-infected patients CaHA was shown to be an appropriate and well tolerated treatment for face lipoatrophy [49]. Complications like hardening and over-collagenization, giving rise to granulomas, is expected to be the same as for poly-lactic acid gel, as the composition of the gel is similar. Up to now these have only been reported after injection into lips, but the material is new for aesthetic indications, and the full range of granulomas risk remains to be exposed.

### Nonbiodegradable synthetic fillers

Nonbiodegradable fillers include silicon gel (or oil), PMMA gel, polyacrylamide hydrogel, and polyalkylimide gel [46,50].

#### *Silicon*

Several forms of liquid injectable silicon oil are FDA-approved for ophthalmic use, but the gel is also used off-label in the cosmetic field. The American Society for Aesthetic Plastic Surgery has warned against the use of liquid injectable silicon for cosmetic purposes pending further investigation, as many years of experience with this material have shown that it may give rise to granulomas up to many years after the injection, occasionally combined with inflammatory changes. Another side effect of silicone oil is its tendency to migrate via circulating tissue macrophages [51].

#### *Polymethylmethacrylate*

Polymethylmethacrylate (PMMA) in smooth microspheres suspended in bovine collagen is FDA-approved, but has no specific indication for HIV lipoatrophy. The bovine collagen in the implant is reabsorbed within a few months, but the presence of the PMMA microspheres



generates new collagen production in that same site, just as it happens for the poly-lactic acid and the calcium hydroxyapatite gels. PMMA gel has been used in Europe for close to a decade and is available in other countries as well. A large series in Brazil described its use in HIV-associated lipoatrophy, but in this study the PMMA microspheres were suspended in carboxymethylcellulose instead of bovine collagen, and a clear systematic collection of safety data was lacking. Reported side effects included postinjection swelling and pain, but the literature contains numerous references about complications with the use of fillers containing PMMA, in particular granulomas. Ultrasound data from this study indicated an increase of dermal thickness, which sustained up to 5 years [46,52].

#### *Polyacrylamide*

Polyacrylamide hydrogel (PAAG) (Aquamid) is an atoxic, stable, highly biocompatible, nonreabsorbable sterile watery gel, which is used for injection into soft tissues. It consists of 2.5% cross-linked polyacrylamide and nonpyrogenic water and is supplied in a disposable 1-ml syringe that is used to inject into the subcutaneous space in a fan-like manner. This results in multiple small deposits, which are readily integrated into the host tissue [53]. PAAG has been in use in Europe for more than 9 years, and clinical studies on patients with HIV lipoatrophy have been carried out in Italy [54,55] and Spain [56,57] with up to 5-year follow-up. No cases of fibrosis or granulomas have been documented. The only registered complications were infections, which were treated with evacuation of the material, antibiotics treatment and later, gel re-injection. Preliminary results of a multicentric, open-label, single-arm, pilot study in 111 HIV-infected patients receiving between 2 and 6 injections every 2–4 weeks were recently presented showing a significant aesthetic benefit of this material for the correction of the facial lipoatrophy with infrequent adverse events registered [58].

#### *Polyalkylimide*

Polyalkylimide (Bio-Alcamid) gel is, like polyacrylamide gel, an atoxic synthetic biopolymer based on 3% polyalkylimide and 97% of apyrogenic water. The gel is considered an inert implant, which induces the host tissue to form a fibrous capsule around the deposit that is claimed to prevent migration. In contrast to polyacrylamide gel it is injected in one session as a large deposit, which makes it easily extractable in case of overcorrection or infection fibrous capsule [59,60]. However, in clinical practice we have seen a substantial number of patients with displacement of the material downwards from the cheek to the mandible rim (unpublished observations). Right after the injection the gel has the same consistency as the surrounding tissue, undetectable to the touch, but over time it can harden and become nodulated. Four studies of 11 [61], 13 [62], 17 [63] and 31 HIV patients [64], respectively, treated with this gel have been

published with a follow-up ranging from 1 to 1.5 years. Complications include migration and infection, the latter occurring up to several years after the injection [64].

### **Adverse events associated to surgical treatments**

Most filling agents are well tolerated, but all are associated with the risk of both acute and delayed adverse reactions [51,52,63]. Reactions can be attributed to the procedural technique itself or the filling agent. Acute events are common, occurring up to several days after procedure, but they are usually transient and of a minor severity. These are predominantly procedure-related and include injection site reactions such as oedema, pain/tenderness, erythema, pruritus, ecchymosis, and injection site bleeding [39,65]. More serious acute events include asymmetry, haematoma, lumps caused by product misdistribution, infection or tissue necrosis [64,65]. Delayed events can occur weeks to years after the procedure, depending on the gel filler used [62]. Major delayed events include low-grade infection, asymmetry, implant dislocation or migration, persistent scarring or discoloration, and granulomatous reactions [62–68].

#### **Management of adverse events**

A low-grade chronic infection due to bacteria growing within the gel is typically seen for the polymer hydrogels (hyaluronic acid gel, polyacrylamide gel, polyalkylimide gel). This will become clinically apparent within 2 weeks of the injection. However, if 1 or 2 ml of gel is injected as one single deposit it may present much later, and the longer the infection lasts the higher the risk is for the bacteria to form a biofilm community within the gel. Therefore, a 2-week antibiotic treatment may be attempted, if the infection develops early, but if there is no response within 3 days the gel should be surgically evacuated and the defect rinsed (still under the same antibiotic coverage) until the infection has disappeared. Most common bacteria involved are gram-positive cocci. A microbiological diagnosis is desirable to guide antimicrobial therapy, but this is not always feasible. An empiric antibiotic treatment may comprise full dose of Moxiphloxacin (400 mg q.i.d.) and Clindamycin (500 mg  $\times$  2). If the infection develops late or if there are relapses, surgical evacuation of the gel is the only option. In case of asymmetry, implant dislocation or migration due to gravity, evacuation of excess or dislocated gel may be necessary. This should be done under antibiotic coverage given in a single dose half a hour to 2 h prior to the injection. Persistent scarring and discolorations may be helped through laser treatment or plastic surgery adjustment. Granulomas are typically seen after injection with silicon gel (oil) and with gels containing microparticles such as PMMA, PLA and CaHA. The current theory behind the development of these

granulomas, up to many years after the injection, is a noncoordinated degradation of microparticles or molecular alterations in their periphery that induce localized de-novo collagen production. Several searches, including prolonged culturing, polymerase chain reaction (PCR), and fluorescence in-situ hybridization (FISH) techniques, have failed to identify the presence of bacteria within these lesions. Treatment recommendations are intralesional injections with steroid, 5-fluoro uracil or allopurinol [62–68]. However, these have been far less effective than surgery or intralesional laser ablation in removing these foreign body granulomas permanently.

## Histopathological findings

Two distinctly different histopathological patterns are seen for the different gels, and these are not related to their life time within the tissue, but rather to their way of acting with surrounding host tissue. The polymer hydrogels (hyaluronic acid, polyacrylamide and polyalkylimide gels) are seen as water-rich 'lakes' which are eventually anchored to the tissue by vessel in-growth. The foreign body reaction to these gels is modest (Fig. 2). The gels that contain microparticles (PMMA, PLA and CaHA) are seen like multiple microspheres or microfragments within the tissue. The carrier gel has quickly disappeared, and macrophages, foreign body giant cells and fibroblasts prevail (Fig. 3). In case of adverse events the most common histopathology changes are the following:

- (1) Hydrogel infection is recognized as an excessive foreign body reaction with enlarged macrophages and giant cells as well as the presence of bacteria and polymorphonuclear granulocytes (Fig. 4).
- (2) Microparticles gels granuloma is recognized as a firm fibrous connective tissue containing scattered microparticles – possibly calcified – numerous macrophages,

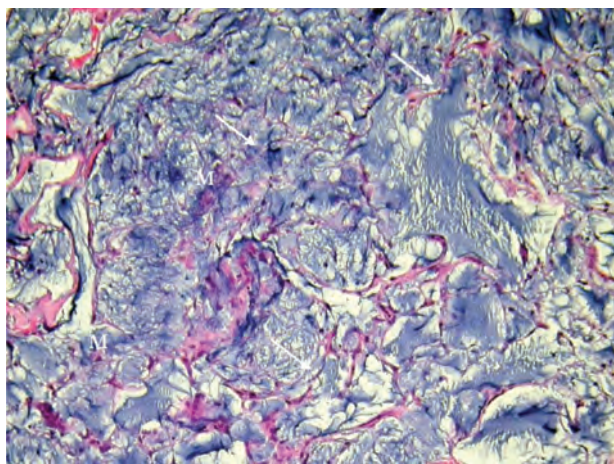


Fig. 2. Histopathological patterns of polymer hydrogels deposit seen as water-rich 'lakes'.

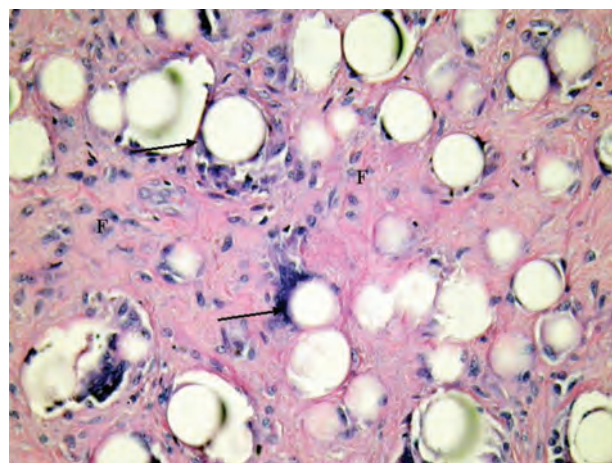


Fig. 3. Histopathological patterns of gels that contain microparticles (PMMA, PLA and CaHA) seen as multiple microspheres or microfragments within the tissue.

giant cells and chronic inflammatory cells and sometimes areas of necrosis as well (Fig. 5).

## Clinical experience and comparative data

Table 1 summarizes published clinical experience in surgical management of facial lipoatrophy. It is surprising how very few studies have assessed safety, efficacy and durability of these interventions and only two partially randomized studies have compared different surgical approaches [54,56]. The first partially randomized study was conducted at the Metabolic Clinic of Modena and Reggio Emilia University. Twenty-four eligible individuals with enough residual subcutaneous fat were offered to receive AFT; the other 35 were blindly assigned to two

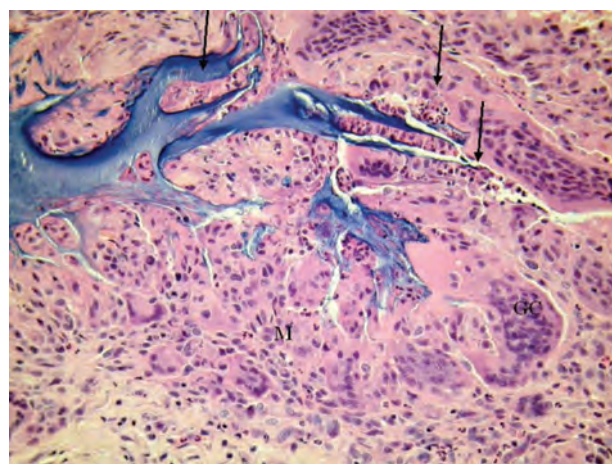
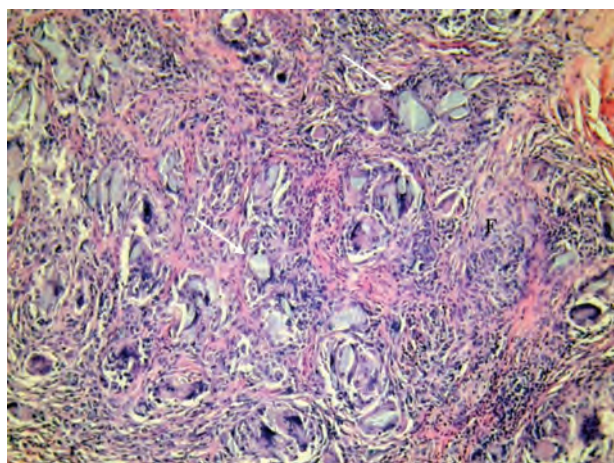


Fig. 4. Hydrogel infection is recognized as an excessive foreign body reaction with enlarged macrophages and giant cells as well as the presence of bacteria and polymorphonuclear granulocytes.





**Fig. 5. Microparticles gels granuloma.** Connective tissue contains scattered microparticles – possible calcified – numerous macrophages, giant cells and chronic inflammatory cells.

different surgical teams who administered a set of PLA or PAAG injections every 4 weeks. The primary end point was the measurement of the cheek region determined by the result of dermal and subcutaneous thickness. Secondary end points included body image evaluation (ABCD questionnaire), facial aesthetic satisfaction (Visual Analogue Scale), and aesthetic pre and postpicture comparisons by independent reviewers. PLA and PAAG groups received a mean of five and six injections, respectively ( $P = \text{n.s.}$ ). After 24 weeks the mean change in fat thickness was  $3.3 \pm 4.1$ ;  $3.5 \pm 4.0$  and  $2.1 \pm 3.0$  mm ( $P = .687$ ) for PLA and PAAG groups, respectively. The mean change in ABCD score result was poorer in the AFT arm as the only difference in all measured parameters. Four serious adverse events were documented in the AFT arm when four patients developed facial fat hypertrophy at the same time of recurrence of fat hypertrophy in the harvest site. This clinical picture has been published as ‘Hamster syndrome’ [47]. This phenomenon have no more been observed since the use of fat hypertrophy for harvest site has been avoided. All three interventional techniques were highly effective in improving the aesthetic satisfaction of the patients.

The second work by Negredo *et al.*, evaluated in a nonrandomized observational study the clinical efficacy of facial infiltrations with autologous fat, poly-lactic acid, and polyacrylamide hydrogel using clinical inspection and facial photographs as well as patient satisfaction, emotional status, and QoL. Patients reaching 48-week follow-up were analyzed. Analysis included 138 patients: 8, 25, and 105 in the AFT, PLA, and PAAG groups, respectively. At baseline, almost 50% of the patients (67/138) presented moderate or severe facial lipoatrophy, but at week 48 only 7.5% (7/93) remained in these advanced grades (no patients from the PAAG group). A new round of infiltrations at week 48 was necessary in 35% (33/93) of

patients (88, 84, and 8% in the AFT, PLA, and PAAG groups, respectively). No serious adverse events were detected with any of the substances. Patient satisfaction and QoL improved significantly in all three groups. Infiltrations with AFT, PLA, or PAAG have appeared to be an effective and well tolerated alternative to repair facial lipoatrophy, at least up to 48 weeks, significantly improving patients’ QoL. Similar results were observed for all degrees of severity and between sexes. PAAG provided the longest lasting benefits. A limitation of this study was the nonhomogeneous distribution of the cases in the three treatment arms. Establishing end points is challenging for comparative studies of facial fillers working by different mechanisms. Assessment by photographs may not lead to reproducible results and is operator-dependent, and the continuation of specific antiretroviral therapies may also influence outcomes. Figure 6 compare aesthetic results of three different surgery techniques using pre and postphotographs. Some attempts of comparison have been made, and funding for additional comparative data is being sought. It is necessary to consider patient-related outcomes such as the assessment of body image, aesthetic perception, depression and QoL. Long-term psychometric outcomes of plastic surgery for treatment of facial lipoatrophy have been described by Orlando *et al.* [69] in an observational, prospective, nonrandomized study of 299 participants (70.8% men). Fifty-four (18.1%) had undergone AFT, 24 (8%) after an initial AFT had needed PLA injections to correct cheek asymmetry, 91 (30.4%) had received only PLA infiltrations, 130 (43.5%) only PAAG infiltrations. Notwithstanding surgery had been limited to the face, all patients had reported body image improvement even though the ABCD questionnaire had no specific questions or items referring to facial lipoatrophy. This positive effect had been evident in the overall sample and in the PLA and PAAG groups, whereas it had reached no statistical significance in the AFT group. It should be noticed that patients treated with AFT use to be patients with mixed form lipodystrophy, so they were more prone to psychological disturbances given that the facial atrophy was only a part of their problem. One of the most striking impacts of surgery had been on depression as assessed by the Beck depression inventory (BDI) [70]. At follow-up, the change in BDI had revealed a significant improvement in the depression score. Nevertheless, analysing the score by single surgery group the change had been significant in the PLA and PAAG groups only [69].

### Choosing the most appropriate surgical procedure

The most important prerequisite to the choice is the expertise of the healthcare worker, particularly plastic reconstructive surgeons. These specialists are the preferred

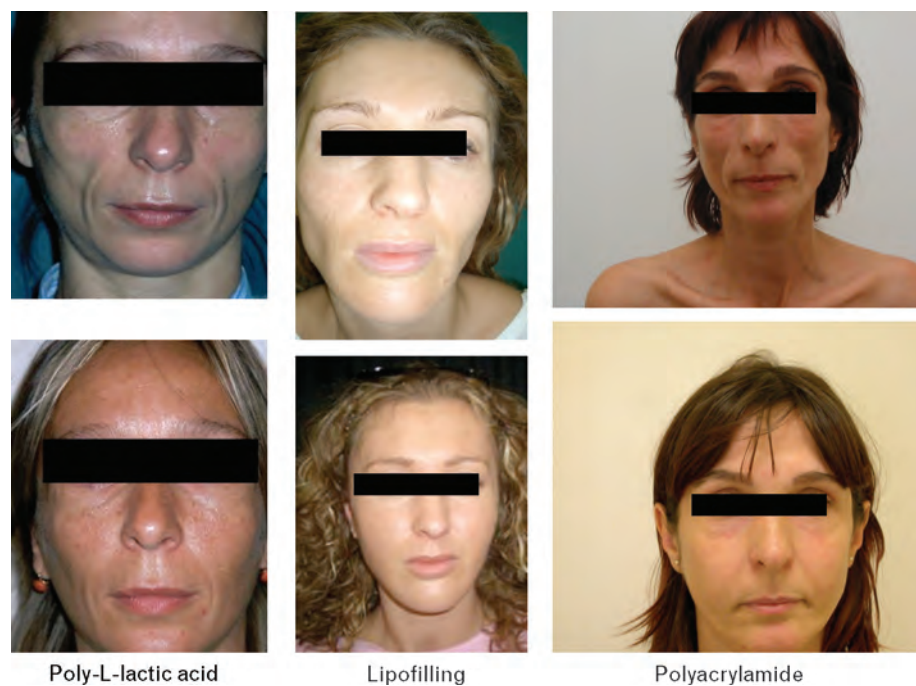Table 1. Published clinical experience in surgical management of facial lipoatrophy.

Material	Author, journal, year	Study type (number of pts)	Efficacy objectively assessed (method)	Efficacy subjectively assessed	Safety (AEs)	Durability (weeks FU)
Poly-L-lactic acid	Carey, <i>Hiv Med</i> , 2009 [68]	RCT (N = 100)	ΔFSTV <sup>a</sup> 14 cm <sup>3</sup> (CT)	↑ Mental Health scale score	Subcutaneous nodules	48
	Carey <i>et al.</i> [86]	RCT (N = 101)	ΔFSTV <sup>a</sup> 0 cm <sup>3</sup> in the intermediate group and -10 cm <sup>3</sup> in the deferred group (US)	↑ Short Form-36 Health Survey and Multidimensional Body-Self Relations Questionnaire-Appearance Scales	No AEs	24
	Moyle <i>et al.</i> [85]	RCT (N = 13)	Yes (US)	↑ VAS <sup>#</sup> and trend in ↑ HADS <sup>c</sup>	1 case of injection-site induration and 9 cases of injection-site nodules	78
	Moyle <i>et al.</i> [87]	RCT (N = 30)	Yes (US)	↑ VAS <sup>#</sup> , photographic assessments, and HADS <sup>c</sup>	1 case of cellulitis and 1 case of bruising	24
	Cattelan <i>et al.</i> [84]	Cohort (N = 50)	Left cheek thickness ↑ 3.3 mm, right cheek thickness ↑ 3.4 mm (US)	↑ over all quality of life (MOS-HIV)	No AEs	48
	Lalaurie <i>et al.</i> [83]	Nonrandomized, prospective (N = 94)	dermal thickness ↑ 2.3 mm (US)	↑ VAS <sup>#</sup> , QoL scores unchanged	1 anaphylactic reaction	NA
Hyaluronic acid	Burgess and Quiroga [82]	Nonrandomized, prospective (N = 61)	NA	↑ Patient's satisfaction	subcutaneous nodules	24
	Valantin <i>et al.</i> [81]	Nonrandomized, prospective Pilot study (N = 50)	median TCT <sup>Δ</sup> ↑ 6.8 mm (US)	Photographic assessments	44% Subcutaneous micronodules	96
	Narins <i>et al.</i> [43]	RCT (N = 138)	NA	↑ Wrinkle Severity Rating Scale and Global Aesthetic Improvement Scale	Local injections site reactions	24
	Bugge <i>et al.</i> [80]	Nonrandomized, prospective (N = 20)	↑ TCT <sup>Δ</sup> 10 mm at week 52 (US)	↑ Global Aesthetic Improvement Scale, VAS, Rosenberg Self-Esteem Scale	No AEs	52
	Goodeham and Solish [45]	Observational (N = 5)	NA	↑ Patient's satisfaction	No AEs	24
	Ritt <i>et al.</i> [44]	Nonrandomized, prospective Pilot study (N = 7)	NA	↑ Patient's satisfaction	No AEs	NA
Polyacrylamide hydrogel	De Santis <i>et al.</i> [55]	Nonrandomized, prospective (N = 50)	Yes (US)	VAS <sup>#</sup> , BDI <sup>b</sup> , ABCD <sup>c</sup>	No AEs	56
	Jones <i>et al.</i> [79]	Nonrandomized, prospective (N = 77)	NA	↑ Patient's satisfaction	No AEs	NA
	Alcalay <i>et al.</i> [52]	Case report	Biopsy	NA	Not reversible granulomatous reaction	NA
	Mole [71]	Nonrandomized, prospective (N = 90)	NA	NA	3 cases of chronic inflammation (dental conflict)	68
	Protapapa <i>et al.</i> [72]	Nonrandomized, prospective (N = 73)	NA	↑ Patient's satisfaction	No AEs	156
	Treacy and Goldberg [59]	Observational, prospective open label (N = 11)	NA	↑ Patient's satisfaction	3 adverse events (swelling and bruising)	78
Bio-Alcamid	Ramon <i>et al.</i> [60]	Nonrandomized, prospective (N = 13)	NA	↑ Patient's satisfaction	1 case of small hematoma	36
	Karim <i>et al.</i> [61]	Nonrandomized, prospective (N = 17)	NA	↑ Mental health and social functioning	4 cases of complications	48
	Loutfy <i>et al.</i> [62]	RCT, open label (N = 31)	NA	Photographic assessment, QoL, depression and anxiety	Mild swelling, redness, bruising and pain	48
	Silvers <i>et al.</i> [78]	Nonrandomized, prospective (N = 100)	↑ skin thickness (US)	Global Aesthetic Improvement Scale, photographic assessment	Mild ecchymosis, edema, erythema, pain, pruritus	78
	Dollfus <i>et al.</i> [73]	Nonrandomized, prospective (N = 6 adolescents)	NA	↑ Patient's satisfaction	NA	NA
	Fontdevila <i>et al.</i> [38]	RCT (N = 26)	↑ mean cheek volume of 1.72 cc (CT)	NA	NA	56
Calcium hydroxylapatite Autologous fat transplant	Olando <i>et al.</i> [69]	RCT (N = 299)	↑ cheek thickness (US)	VAS <sup>#</sup> , ABCD <sup>c</sup> , BDI <sup>b</sup>	No AEs	48
	Burnout <i>et al.</i> [77]	Nonrandomized, prospective (N = 33)	3 independent medical specialists evaluation	↑ Patient's satisfaction	No AEs	52
	Strauch <i>et al.</i> [76]	Nonrandomized, prospective (N = 5)	NA	↑ Patient's satisfaction	No AEs	48-96
	Caye <i>et al.</i> [75]	Nonrandomized, prospective (N = 29)	NA	Photographic assessment	No AEs	24
	Levan <i>et al.</i> [74]	Nonrandomized, prospective (N = 15)	↑ fat thickness 10.5 mm on the left side and 10 mm right side (MR)	↑ Patient's satisfaction	6 cases of moderate swelling at the injection sites, 5 cases of moderate pain at the donor sites	24
	Guaraldi <i>et al.</i> [47]	Nonrandomized, prospective (N = 41)	↑ cheeks subcutaneous 14.6 mm (US)	NA	Hamster syndrome in 4 pts	NA

↑ increased, # VAS, Visual Analogue Scale, ° HADS, Hospital Anxiety and Depression Scale, ΔTCT, median total cutaneous thickness.

<sup>a</sup> ΔFSTV, facial soft tissue value change.<sup>b</sup> BDI, Beck Depression Inventory.<sup>c</sup> ABCD, assessment of body change and distress.





**Fig. 6. Aesthetic results of three different surgical approaches.** Before and after photographs.

ones and the only allowed to perform autologous fat transplant. Given the excellent aesthetic result of lipofilling, and both biodegradable and nonbiodegradable fillers the choice of the best surgical procedure is not a matter of aesthetic issues [39–46]. Biodegradable agents offer a greater safety profile, having a lower incidence of adverse effects compared to nonreabsorbable products. Their main limitation is short longevity, and hence the need for re-injection to maintain aesthetic benefits over time which increases treatment costs. Biodegradable fillers are preferable when there is potential for recovery of the underlying condition, which would appear the case for HIV facial lipoatrophy, whenever thymidine analogue-sparing regimens are available. These fillers should be the first choice in younger people suffering of mild to moderate facial lipoatrophy, in order to allow a better adaptation of the filler with the physiological aging process, unless grade 4 facial lipoatrophy when high-volume injection is needed. This

result, indeed, can be obtained mainly with AFT, when feasible, or with nonbiodegradable fillers. In case of patients often suffering from sinusitis or dental granuloma, severe or recurrent acne or undergoing odonto-stomathologic procedure, nonbiodegradable fillers should be avoided because of the risk of local infection or granuloma that may potentially occur years after the filling procedure as long-term complications. Antibiotic prophylaxis must be considered in patients treated with synthetic materials who will undergo a dental treatment. Short-term complications, mainly represented by local oedema, infection and bleeding are few when fillers are injected with small-gauge needle, and always self-limiting, but they may occur hypothetically with all fillers. There may be different policy reimbursements in each country, where sometimes insurances may cover these procedures, and these considerations underpin all the comments on the different costs. In general it can be assumed that lipofilling

**Table 2. Choice criteria of surgical treatment of HIV-associated facial lipoatrophy.**

	Autologous fat transplant	Biodegradable fillers	Nonbiodegradable fillers
Expertise of the healthcare worker	Highly required	Non required highly experience	Highly required
Safety	Potential short-term complications as local oedema, infection and bleeding	Potential subcutaneous skin nodules after injecting polylactic acid	Potential long-term complications as local infection or granuloma
Severity	Any degree of volume	Preferable when no need of high volume injection	Preferable when need of high-volume injection
Costs	Presumably most costly	Potentially costly when many retouches needed	Costly but definite
Age	Preferable in all ages	Preferable in younger people	Preferable in older people
FDA approval	No	Polylactic acid, hydroxyapatite, collagen, hyaluronic acid	Polymethyl methacrylate (PMMA)
Skin quality	Thick skin	Thin skin	Thick skin

procedure is most costly, but it may prove to obtain a permanent result, though less costly, in comparison to the cost of multiple surgical procedures needed for facial implants and in particular with biodegradable filler that needs most of the time yearly retouch procedures. A parallel benefit for the patient with the use of AFT is the simultaneous treatment of fat accumulation that can justify this approach. Table 2 summarizes clinical considerations to be taken into account when choosing different surgical procedures. Patients must be informed about the options that suit their necessities, and participate to the decision of what material will be used in his or her case.

## Conclusion

Facial lipoatrophy is a stigmatizing feature of HIV-related lipodystrophy. Even if we hypothesize that its prevalence is supposed to decrease with the advent of the new drugs, it still remains for many patients a cause of self-image and self-esteem detriment, and depression. Some medical attempts have been made to ameliorate lipodystrophy, but the results are slow and incomplete. Plastic surgery seems to be a well tolerated, feasible tool to treat HIV-related face lipoatrophy. It has proved to be effective even in managing the psychological consequences of lipodystrophy, and in improving patients' QoL. Different techniques are available (AFT, injections of absorbable or nonabsorbable materials) with various reports in literature about safety and durability of the good aesthetic results. The choice of the technique to be used depends on the face lipoatrophy severity, on the availability of subcutaneous fat graft, and on the different policy reimbursements of these procedures in each country. Although very low, the risk of adverse events related to face surgery still remains, so that the expertise of the healthcare worker, particularly the plastic reconstructive surgeons involved in these procedures, is highly required. New controlled study would be needed to define the long-term benefits and safety of the different surgical techniques to treat HIV-related face lipoatrophy.

## References

- Carr A, Samaras K, Burton S, Law M, Freund J, Chisholm DJ, Cooper DA. A syndrome of peripheral lipodystrophy, hyperlipidaemia and insulin resistance in patients receiving HIV protease inhibitors. *AIDS* 1998; **12**:F51–F58.
- Lo JC, Mulligan K, Tai VW, Algren H, Schambelan M. 'Buffalo hump' in men with HIV-1 infection. *Lancet* 1998; **351**:867–870.
- Stricker RB, Goldberg B. Fat accumulation and HIV-1 protease inhibitors. *Lancet* 1998; **352**:1392.
- Saint-Marc T, Partisani M, Poizot-Martin I, Bruno F, Rouviere O, Lang JM, et al. A syndrome of peripheral fat wasting (lipodystrophy) in patients receiving long-term nucleoside analogue therapy. *AIDS* 1999; **13**:1659–1667.
- Miller KD, Jones E, Yanovski JA, Shankar R, Feuerstein I, Falloon J. Visceral abdominal-fat accumulation associated with use of indinavir. *Lancet* 1998; **351**:871–875.
- Bacchetti P, Gripshover B, Grunfeld C, Heymsfield S, McCreath H, Osmond D, et al. Fat distribution in men with HIV infection. *J Acquir Immune Defic Syndr* 2005; **40**:121–131.
- Fat distribution in women with HIV infection. *J Acquir Immune Defic Syndr* 2006; **42**:562–571.
- Lichtenstein KA, Ward DJ, Moorman AC, Delaney KM, Young B, Palella FJ Jr, et al. Clinical assessment of HIV-associated lipodystrophy in an ambulatory population. *AIDS* 2001; **15**:1389–1398.
- Gopinath R, Hutcheon M, Cheema-Dhadli S, Halperin M. Chronic lactic acidosis in a patient with acquired immunodeficiency syndrome and mitochondrial myopathy: biochemical studies. *J Am Soc Nephrol* 1992; **3**:1212–1219.
- Ribera E, Paradineiro JC, Curran A, Saulea S, Garcia-Arumi E, Castella E, et al. Improvements in subcutaneous fat, lipid profile, and parameters of mitochondrial toxicity in patients with peripheral lipoatrophy when stavudine is switched to tenofovir (LIPOTEST study). *HIV Clin Trials* 2008; **9**:407–417.
- Kitahata MM, Gange SJ, Abraham AG, Merriman B, Saag MS, Justice AC, et al. Effect of early versus deferred antiretroviral therapy for HIV on survival. *N Engl J Med* 2009; **360**:1815–1826.
- Nguyen A, Calmy A, Schiffer V, Bernasconi E, Battegay M, Opravil M, et al. Lipodystrophy and weight changes: data from the Swiss HIV Cohort Study, 2000–2006. *HIV Med* 2008; **9**:142–150.
- Mutimura E, Stewart A, Rheeder P, Crowther NJ. Metabolic function and the prevalence of lipodystrophy in a population of HIV-infected African subjects receiving highly active antiretroviral therapy. *J Acquir Immune Defic Syndr* 2007; **46**:451–455.
- Mercier S, Gueye NF, Cournil A, Fontbonne A, Copin N, Ndiaye I, et al. Lipodystrophy and metabolic disorders in HIV-1-infected adults on 4- to 9-year antiretroviral therapy in Senegal: a case-control study. *J Acquir Immune Defic Syndr* 2009; **51**:224–230.
- Miller J, Carr A, Smith D, Emery S, Law MG, Grey P, Cooper DA. Lipodystrophy following antiretroviral therapy of primary HIV infection. *AIDS* 2000; **14**:2406–2407.
- Martinez E, Mocroft A, Garcia-Viejo MA, Perez-Cuevas JB, Blanco JL, Mallolas J, et al. Risk of lipodystrophy in HIV-1-infected patients treated with protease inhibitors: a prospective cohort study. *Lancet* 2001; **357**:592–598.
- Coleman S, Saboeiro A, Sengelmann R. A comparison of lipoatrophy and aging: volume deficits in the face. *Aesthetic Plast Surg* 2009; **33**:14–21.
- Blanch J, Rousaud A, Martinez E, De Lazzari E, Milinkovic A, Peri JM, et al. Factors associated with severe impact of lipodystrophy on the quality of life of patients infected with HIV-1. *Clin Infect Dis* 2004; **38**:1464–1470.
- Blanch J, Rousaud A, Martinez E, De Lazzari E, Peri JM, Milinkovic A, et al. Impact of lipodystrophy on the quality of life of HIV-1-infected patients. *J Acquir Immune Defic Syndr* 2002; **31**:404–407.
- Collins E, Wagner C, Walmsley S. Psychosocial impact of the lipodystrophy syndrome in HIV infection. *AIDS Read* 2000; **10**:546–550.
- Martin A, Smith DE, Carr A, Ringland C, Amin J, Emery S, et al. Reversibility of lipoatrophy in HIV-infected patients 2 years after switching from a thymidine analogue to abacavir: the MITOX Extension Study. *AIDS* 2004; **18**:1029–1036.
- McComsey GA, Ward DJ, Hesselthaler SM, Sension MG, Shalit P, Lonergan JT, et al. Improvement in lipoatrophy associated with highly active antiretroviral therapy in human immunodeficiency virus-infected patients switched from stavudine to abacavir or zidovudine: the results of the TARHEEL study. *Clin Infect Dis* 2004; **38**:263–270.
- Moyle GJ, Sabin CA, Cartledge J, Johnson M, Wilkins E, Churchill D, et al. A randomized comparative trial of tenofovir DF or abacavir as replacement for a thymidine analogue in persons with lipodystrophy. *AIDS* 2006; **20**:2043–2050.
- Mallon PW, Miller J, Kovacic JC, Kent-Hughes J, Norris R, Samaras K, et al. Effect of pravastatin on body composition and markers of cardiovascular disease in HIV-infected men: a randomized, placebo-controlled study. *AIDS* 2006; **20**:1003–1010.
- Sheth SH, Larson RJ. The efficacy and safety of insulin-sensitizing drugs in HIV-associated lipodystrophy syndrome: a meta-analysis of randomized trials. *BMC Infect Dis* 2010; **10**:183.

26. Calmy A, Bloch M, Wand H, Delhumeau C, Finlayson R, Rafferty M, Norris R, et al. **No significant effect of uridine or pravastatin treatment for HIV lipoatrophy in men who have ceased thymidine analogue nucleoside reverse transcriptase inhibitor therapy: a randomized trial.** *HIV Med* 2010; **11**:493–501.
27. McComsey G, Walker U, Budhathoki C, Su Z, Currier J, Kosmiski J, et al. **Uridine supplementation in the management of HIV lipoatrophy: results of ACTG 5229.** *Conference on Retroviruses and Opportunistic Infections.* San Francisco; 2010 [abstract 131].
28. Benn P, Ruff C, Cartledge J, Sauret V, Copas A, Linney A, et al. **Overcoming subjectivity in assessing facial lipoatrophy: is there a role for three-dimensional laser scans?** *HIV Med* 2003; **4**:325–331.
29. Gulizia R, Vercelli A, Gervasoni C, Ortu M, Calliada F, Troia G, et al. **Controversy concerning role of ultrasonographic lipoatrophy assessments in HIV patients.** *AIDS* 2006; **20**:789–790.
30. James J, Carruthers A, Carruthers J. **HIV-associated facial lipoatrophy.** *Dermatol Surg* 2002; **28**:979–986.
31. Christensen L, Breiting V, Janssen M, Vuust J, Hogdall E. **Adverse reactions to injectable soft tissue permanent fillers.** *Aesthetic Plast Surg* 2005; **29**:34–48.
32. Fontdevila J, Berenguer J, Prades E, Pujol T, Guisantes E, Serra-Renom J, et al. **Validation of a simple classification for facial lipoatrophy in HIV-infected adults.** *Antiviral Ther* 2007; **12** (Suppl 2):L31.
33. Cash. **The psychology of physical appearance: aesthetics, attributes and images.** In: *Body images: development, deviance and change.* New York: Guilford; 1990. pp. 51–79.
34. Guaraldi G, Orlando G, Murri R, Vandelli M, De Paola M, Beghetto B, et al. **Quality of life and body image in the assessment of psychological impact of lipodystrophy: validation of the Italian version of assessment of body change and distress questionnaire.** *Qual Life Res* 2006; **15**:173–178.
35. Carey D, Wand H, Martin A, Rothwell S, Emery S, Cooper DA, Carr A. **Evaluation of ultrasound for assessing facial lipoatrophy in a randomized, placebo-controlled trial.** *AIDS* 2005; **19**:1325–1327.
36. Martinez E, Bianchi L, Garcia-Viejo MA, Bru C, Gatell JM. **Sonographic assessment of regional fat in HIV-1-infected people.** *Lancet* 2000; **356**:1412–1413.
37. Padilla S, Gallego JA, Masia M, Gutierrez F. **Single-slice computed tomography and anthropometric skinfold analysis for evaluation of facial lipoatrophy in HIV-infected patients.** *Clin Infect Dis* 2004; **39**:1848–1851.
38. Fontdevila J, Serra-Renom JM, Raigosa M, Berenguer J, Guisantes E, Prades E, et al. **Assessing the long-term viability of facial fat grafts: an objective measure using computed tomography.** *Aesthet Surg J* 2008; **28**:380–386.
39. Coleman SR. **Facial recontouring with lipostructure.** *Clin Plast Surg* 1997; **24**:347–367.
40. Coleman SR. **Structural fat grafts: the ideal filler?** *Clin Plast Surg* 2001; **28**:111–119.
41. Carraway JH, Mellow CG. **Syringe aspiration and fat concentration: a simple technique for autologous fat injection.** *Ann Plast Surg* 1990; **24**:293–296; discussion; 297.
42. Lam SM, Azizzadeh B, Graivier M. **Injectable poly-L-lactic acid (Sculptra): technical considerations in soft-tissue contouring.** *Plast Reconstr Surg* 2006; **118**:55S–63S.
43. Narins RS, Brandt F, Leyden J, Lorenc ZP, Rubin M, Smith S. **A randomized, double-blind, multicenter comparison of the efficacy and tolerability of Restylane versus Zyplast for the correction of nasolabial folds.** *Dermatol Surg* 2003; **29**:588–595.
44. Ritt MJ, Hillebrand-Haverkort ME, ten Veen JH. **Local treatment of facial lipodystrophy in patients receiving HIV protease inhibitor therapy.** *Acta Chir Plast* 2001; **43**:54–56.
45. Gooderham M, Solish N. **Use of hyaluronic acid for soft tissue augmentation of HIV-associated facial lipodystrophy.** *Dermatol Surg* 2005; **31**:104–108.
46. Oyafuso LK SM, Troppe BM. **Polymethylmethacrylate (PMMA) for facial atrophy treatment: 5 years follow-up.** *Program and abstracts of the XV International AIDS Conference; Bangkok, Thailand.* Abstract MoOrB1060 2004.
47. Guaraldi G, De Fazio D, Orlando G, Murri R, Wu A, Guaraldi P, Esposito R. **Facial lipohypertrophy in HIV-infected subjects who underwent autologous fat tissue transplantation.** *Clin Infect Dis* 2005; **40**:e13–e15.
48. Kates LC, Fitzgerald R. **Poly-L-lactic acid injection for HIV-associated facial lipoatrophy: treatment principles, case studies, and literature review.** *Aesthet Surg J* 2008; **28**:397–403.
49. Carruthers A, Carruthers J. **Evaluation of injectable calcium hydroxylapatite for the treatment of facial lipoatrophy associated with human immunodeficiency virus.** *Dermatol Surg* 2008; **34**:1486–1499.
50. Jones D. **HIV facial lipoatrophy: causes and treatment options.** *Dermatol Surg* 2005; **31**:1519–1529; discussion 1529.
51. Saylan Z. **Facial fillers and their complications.** *Aesthet Surg J* 2003; **23**:221–224.
52. Alcalay J, Alcalay R, Gat A, Yorav S. **Late-onset granulomatous reaction to Artecoll.** *Dermatol Surg* 2003; **29**:859–862.
53. Christensen LH, Nielsen JB, Mouritsen L, Sorensen M, Lose G. **Tissue integration of polyacrylamide hydrogel: an experimental study of periurethral, perivesical, and mammary gland tissue in the pig.** *Dermatol Surg* 2008; **34** (Suppl 1):S68–S77; discussion S77.
54. Guaraldi G, Orlando G, De Fazio D, De Lorenzi I, Rottino A, De Santis G, et al. **Comparison of three different interventions for the correction of HIV-associated facial lipoatrophy: a prospective study.** *Antivir Ther* 2005; **10**:753–759.
55. De Santis G, Jacob V, Baccarani A, Pedone A, Pinelli M, Spaggiari A, Guaraldi G. **Polyacrylamide hydrogel injection in the management of human immunodeficiency virus-related facial lipoatrophy: a 2-year clinical experience.** *Plast Reconstr Surg* 2008; **121**:644–653.
56. Negro E, Higuera C, Adell X, Martinez JC, Martinez E, Puig J, et al. **Reconstructive treatment for antiretroviral-associated facial lipoatrophy: a prospective study comparing autologous fat and synthetic substances.** *AIDS Patient Care STDS* 2006; **20**:829–837.
57. Negro E, Puig J, Aldea D, Medina M, Estany C, Perez-Alvarez N, et al. **Four-year safety with polyacrylamide hydrogel to correct antiretroviral-related facial lipoatrophy.** *AIDS Res Hum Retrovirus* 2009; **25**:451–455.
58. Brazille P, Carbonnel E, Grataloup C, Mercier S, Gillaizeau F, Duracinsky M, et al. **Polyacrylamide hydrogel injection in the management of human immunodeficiency virus-related facial lipoatrophy: results of the open-label study LIPOPHILL.** *5th IAS Conference on HIV Pathogenesis, Treatment and Prevention.* Cape Town, 19–22 July, 2009.
59. Treacy PJ, Goldberg DJ. **Use of a biopolymer polyalkylimide filler for facial lipodystrophy in HIV-positive patients undergoing treatment with antiretroviral drugs.** *Dermatol Surg* 2006; **32**:804–808.
60. Ramon Y, Fodor L, Ullmann Y. **Preliminary experiences with Bio-Alcamid in HIV facial lipoatrophy.** *Dermatology* 2007; **214**:151–154.
61. Karim RB, de Lint CA, van Galen SR, van Rozelaar L, Nieuwkerk PT, Askarizadeh E, Hage JJ. **Long-term effect of polyalkylimide gel injections on severity of facial lipoatrophy and quality of life of HIV-positive patients.** *Aesthetic Plast Surg* 2008; **32**:873–878.
62. Loutfy MR, Raboud JM, Antoniou T, Kovacs C, Shen S, Halpenny R, et al. **Immediate versus delayed polyalkylimide gel injections to correct facial lipoatrophy in HIV-positive patients.** *AIDS* 2007; **21**:1147–1155.
63. Karim RB, Hage JJ, van Rozelaar L, Lange CA, Raaijmakers J. **Complications of polyalkylimide 4% injections (Bio-Alcamid): a report of 18 cases.** *J Plast Reconstr Aesthet Surg* 2006; **59**:1409–1414.
64. Christensen L. **Normal and pathologic tissue reactions to soft tissue gel fillers.** *Dermatol Surg* 2007; **33** (Suppl 2):S168–S175.
65. Lowe NJ, Maxwell CA, Patnaik R. **Adverse reactions to dermal fillers: review.** *Dermatol Surg* 2005; **31**:1616–1625.
66. Lemperle G, Rullan PP, Gauthier-Hazan N. **Avoiding and treating dermal filler complications.** *Plast Reconstr Surg* 2006; **118**:92S–107S.
67. Gladstone HB, Cohen JL. **Adverse effects when injecting facial fillers.** *Semin Cutan Med Surg* 2007; **26**:34–39.
68. Carey D, Baker D, Petoumenos K, Chuah J, Rogers GD, Watson J, et al. **Poly-L-lactic acid for HIV-1 facial lipoatrophy: 48-week follow-up.** *HIV Med* 2009; **10**:163–172.
69. Orlando G, Guaraldi G, De Fazio D, Rottino A, Grisotti A, Blini M, et al. **Long-term psychometric outcomes of facial lipoatrophy therapy: forty-eight-week observational, nonrandomized study.** *AIDS Patient Care STDS* 2007; **21**:833–842.



70. Beck AT, Steer RA. **Internal consistencies of the original and revised Beck Depression Inventory.** *J Clin Psychol* 1984; **40**:1365–1367.
71. Mole B. **Lasting treatment of facial HIV and non HIV lipotrophies through the use of SAM GoreTex malar implants and polyacrylamide hydrogel filler Eutrophill. About 90 consecutive cases.** *Ann Chir Plast Esthet* 2006; **51**:129–141.
72. Protopapa C, Sito G, Caporale D, Cammarota N. **Bio-Alcamid in drug-induced lipodystrophy.** *J Cosmet Laser Ther* 2003; **5**:226–230.
73. Dollfus C, Blanche S, Trocme N, Funck-Brentano I, Bonnet F, Levan P. **Correction of facial lipotrophy using autologous fat transplants in HIV-infected adolescents.** *HIV Med* 2009; **10**:263–268.
74. Levan P, Nguyen TH, Lallemand F, Mazetier L, Mimoun M, Rozenbaum W, Girard PM. **Correction of facial lipotrophy in HIV-infected patients on highly active antiretroviral therapy by injection of autologous fatty tissue.** *AIDS* 2002; **16**:1985–1987.
75. Caye N, Le Fourn B, Pannier M. **Surgical treatment of facial lipotrophy.** *Ann Chir Plast Esthet* 2003; **48**:2–12.
76. Strauch B, Baum T, Robbins N. **Treatment of human immunodeficiency virus-associated lipodystrophy with dermafat graft transfer to the malar area.** *Plast Reconstr Surg* 2004; **113**:363–370; discussion 371–362.
77. Burnouf M, Buffet M, Schwarzwinger M, Roman P, Bui P, Prevot M, et al. **Evaluation of Coleman lipostructure for treatment of facial lipotrophy in patients with human immunodeficiency virus and parameters associated with the efficiency of this technique.** *Arch Dermatol* 2005; **141**:1220–1224.
78. Silvers SL, Eviatar JA, Echavez MI, Pappas AL. **Prospective, open-label, 18-month trial of calcium hydroxylapatite (Radiesse) for facial soft-tissue augmentation in patients with human immunodeficiency virus-associated lipotrophy: one-year durability.** *Plast Reconstr Surg* 2006; **118**:34S–45S.
79. Jones DH, Carruthers A, Orentreich D, Brody HJ, Lai MY, Azen S, Van Dyke GS. **Highly purified 1000-cSt silicone oil for treatment of human immunodeficiency virus-associated facial lipotrophy: an open pilot trial.** *Dermatol Surg* 2004; **30**:1279–1286.
80. Bugge H, Negaard A, Skeie L, Bergersen B. **Hyaluronic acid treatment of facial fat atrophy in HIV-positive patients.** *HIV Med* 2007; **8**:475–482.
81. Valantin MA, Aubron-Olivier C, Ghosn J, Laglenne E, Pauchard M, Schoen H, et al. **Poly-lactic acid implants (New-Fill) to correct facial lipotrophy in HIV-infected patients: results of the open-label study VEGA.** *AIDS* 2003; **17**:2471–2477.
82. Burgess CM, Quiroga RM. **Assessment of the safety and efficacy of poly-L-lactic acid for the treatment of HIV-associated facial lipotrophy.** *J Am Acad Dermatol* 2005; **52**:233–239.
83. Lafaurie M, Dolivo M, Porcher R, Rudant J, Madelaine I, Molina JM. **Treatment of facial lipotrophy with intradermal injections of poly-lactic acid in HIV-infected patients.** *J Acquir Immune Defic Syndr* 2005; **38**:393–398.
84. Cattelan AM, Bauer U, Trevenzoli M, Sasset L, Campostrini S, Facchin C, et al. **Use of poly-lactic acid implants to correct facial lipotrophy in human immunodeficiency virus 1-positive individuals receiving combination antiretroviral therapy.** *Arch Dermatol* 2006; **142**:329–334.
85. Moyle GJ, Brown S, Lysakova L, Barton SE. **Long-term safety and efficacy of poly-L-lactic acid in the treatment of HIV-related facial lipotrophy.** *HIV Med* 2006; **7**:181–185.
86. Carey DL, Baker D, Rogers GD, Petoumenos K, Chuah J, Easey N, et al. **A randomized, multicenter, open-label study of poly-L-lactic acid for HIV-1 facial lipotrophy.** *J Acquir Immune Defic Syndr* 2007; **46**:581–589.
87. Moyle GJ, Lysakova L, Brown S, Sibbain N, Healy J, Priest C, et al. **A randomized open-label study of immediate versus delayed poly-lactic acid injections for the cosmetic management of facial lipotrophy in persons with HIV infection.** *HIV Med* 2004; **5**:82–87.