

ORIGINAL ARTICLE

Monkeypox Virus Infection in Humans across 16 Countries — April–June 2022

J.P. Thornhill, S. Barkati, S. Walmsley, J. Rockstroh, A. Antinori, L.B. Harrison, R. Palich, A. Nori, I. Reeves, M.S. Habibi, V. Apea, C. Boesecke, L. Vandekerckhove, M. Yakubovsky, E. Sendagorta, J.L. Blanco, E. Florence, D. Moschese, F.M. Maltez, A. Goorhuis, V. Pourcher, P. Migaud, S. Noe, C. Pintado, F. Maggi, A.-B.E. Hansen, C. Hoffmann, J.I. Lezama, C. Mussini, A.M. Cattelan, K. Makofane, D. Tan, S. Nozza, J. Nemeth, M.B. Klein, and C.M. Orkin, for the SHARE-net Clinical Group*

ABSTRACT

BACKGROUND

Before April 2022, monkeypox virus infection in humans was seldom reported outside African regions where it is endemic. Currently, cases are occurring worldwide. Transmission, risk factors, clinical presentation, and outcomes of infection are poorly defined.

METHODS

We formed an international collaborative group of clinicians who contributed to an international case series to describe the presentation, clinical course, and outcomes of polymerase-chain-reaction–confirmed monkeypox virus infections.

RESULTS

We report 528 infections diagnosed between April 27 and June 24, 2022, at 43 sites in 16 countries. Overall, 98% of the persons with infection were gay or bisexual men, 75% were White, and 41% had human immunodeficiency virus infection; the median age was 38 years. Transmission was suspected to have occurred through sexual activity in 95% of the persons with infection. In this case series, 95% of the persons presented with a rash (with 64% having <10 lesions), 73% had anogenital lesions, and 41% had mucosal lesions (with 54 having a single genital lesion). Common systemic features preceding the rash included fever (62%), lethargy (41%), myalgia (31%), and headache (27%); lymphadenopathy was also common (reported in 56%). Concomitant sexually transmitted infections were reported in 109 of 377 persons (29%) who were tested. Among the 23 persons with a clear exposure history, the median incubation period was 7 days (range, 3 to 20). Monkeypox virus DNA was detected in 29 of the 32 persons in whom seminal fluid was analyzed. Antiviral treatment was given to 5% of the persons overall, and 70 (13%) were hospitalized; the reasons for hospitalization were pain management, mostly for severe anorectal pain (21 persons); soft-tissue superinfection (18); pharyngitis limiting oral intake (5); eye lesions (2); acute kidney injury (2); myocarditis (2); and infection-control purposes (13). No deaths were reported.

CONCLUSIONS

In this case series, monkeypox manifested with a variety of dermatologic and systemic clinical findings. The simultaneous identification of cases outside areas where monkeypox has traditionally been endemic highlights the need for rapid identification and diagnosis of cases to contain further community spread.

The authors' full names, academic degrees, and affiliations are listed in the Appendix. Prof. Orkin can be contacted at c.m.orkin@qmul.ac.uk, or at the SHARE Collaborative, Centre for Immunobiology, Blizard Institute, Queen Mary University of London, 4 Newark St., London E1 2AT, United Kingdom.

*The investigators in the SHARE-net clinical group are listed in the Supplementary Appendix, available at [NEJM.org](https://www.nejm.org).

Drs. Thornhill, Barkati, Klein, and Orkin contributed equally to this article.

This article was published on July 21, 2022, at [NEJM.org](https://www.nejm.org).

DOI: [10.1056/NEJMoa2207323](https://doi.org/10.1056/NEJMoa2207323)

Copyright © 2022 Massachusetts Medical Society.

MONKEYPOX VIRUS, A ZOONOTIC ORTHOPOX DNA virus related to the virus that causes smallpox, was first described in humans in 1970 in the Democratic Republic of Congo (formerly Zaire).¹ Sporadic outbreaks of infection have been reported in Africa, typically originating from contact with wildlife reservoirs (particularly rodents).² Such outbreaks and travel-associated cases outside Africa have had limited secondary spread, and therefore human-to-human transmission has been deemed inefficient.³⁻⁹ Despite the fact that monkeypox virus has circulated for decades in regions where it has traditionally been endemic, research into monkeypox has been neglected and underfunded. Since early May 2022, more than 3000 monkeypox virus infections have been reported in more than 50 countries across five regions, prompting the World Health Organization to declare monkeypox an “evolving threat of moderate public health concern” on June 23, 2022.^{10,11}

Transmission of monkeypox virus occurs through large respiratory droplets, close or direct contact with skin lesions, and possibly through contaminated fomites.¹² There is no clear evidence of sexual transmission through seminal or vaginal fluids. Vertical transmission and fetal deaths have been described.¹³

Endemic monkeypox is generally self-limited, with clade-dependent case fatality rates of 1 to 10%.⁹ Illness typically begins with fever, followed by the development of multiple papular, vesiculopustular, and ulcerative lesions on the face and body and prominent lymphadenopathy.^{9,14} Complications include pneumonitis, encephalitis, keratitis, and secondary bacterial infections.¹⁴ Young children and immunocompromised persons, including persons living with human immunodeficiency virus (HIV) infection, have been reported to be at increased risk for severe outcomes, but whether effective antiretroviral therapy (ART) for HIV infection modifies this risk is unknown.¹⁵

The current global outbreak of monkeypox virus infection in humans suggests changes in biologic aspects of the virus, changes in human behavior, or both; such changes might be driven by waning smallpox immunity, relaxation of coronavirus disease 2019 (Covid-19) prevention measures, resumption of international travel, and sexual interactions associated with large gatherings.¹⁶ To date, the current spread has dispropor-

tionately affected men who are gay or bisexual and other men who have sex with men, which suggests amplification of transmission through sexual networks.

Phylogenetic analyses suggest that the virus has circulated undetected for some time outside areas where it has been endemic, possibly masquerading as other sexually transmitted infections (STIs).¹⁷ The current international case definitions (Table S1 and Fig. S1 in the Supplementary Appendix, available with the full text of this article at NEJM.org) may not be adequate to reflect the changing spectrum of clinical presentations, allow early identification, clarify transmission routes, and inform international public health policies and clinical trials. The case series we report here may help to inform the response.

METHODS

CASE DEFINITION AND IDENTIFICATION

We used the U.K. Health Security Agency (UKHSA) definition of a confirmed case: a laboratory-confirmed monkeypox virus infection defined by a positive result on monkeypox virus polymerase-chain-reaction (PCR) assay in a specimen from any anatomical site.¹⁸ The type of clinically qualified PCR assay used for the identification of monkeypox virus infections was locally determined on the basis of availability and guidelines.

In response to the worldwide outbreaks, academic researchers within the London-based Sexual Health and HIV All East Research (SHARE) Collaborative contacted peers in affected countries through informal clinical and research networks and formed a global collaborative group (SHARE-net). Members of this group contributed to a convenience-sample case series in the interests of improving case identification. The geographic distribution of SHARE-net contributing sites is shown in Figure 1.

DATA COLLECTION

Each contributing center completed a deidentified structured case-report spreadsheet developed on May 31, 2022 (Fig. S2). Drop-down menus and free-text fields were used. The case-report spreadsheet captured clinical data and was not part of a research protocol. Variables of interest were derived from case definitions that preceded this outbreak and from evolving international case

definitions. The case-report spreadsheet was iteratively refined on the basis of growing clinical experience within our network. We particularly focused on potential exposures, demographic characteristics, early symptoms, clinical findings, and diagnosis. Infections diagnosed since April 27, 2022, were reported between June 1 and June 24, 2022. Templates were provided for uniform presentation of the clinical image Web library (available in the Supplementary Appendix).

ETHICAL CONSIDERATIONS

Persons with PCR-confirmed monkeypox were invited to contribute to the case series by their health care provider. Written informed consent was obtained in accordance with local standards and maintained in the participants’ clinical file, along with local institutional review board approval when required. Separate image-specific consent was obtained for the use of images included in this report. Deidentified data were securely transferred to the coordinating site and stored and analyzed within the Queen Mary University of London Barts Cancer Institute data safe haven.

STATISTICAL ANALYSIS

Data were analyzed with the use of SPSS software, version 28 (IBM). Aggregate or deidentified data are presented to avoid deductive disclosure of the identities of the persons with infection.

RESULTS

PERSONS WITH INFECTION

A total of 528 cases of confirmed human monkeypox infection from five continents, 16 countries, and 43 clinical sites are included in this series (Fig. 1). Demographic and clinical characteristics of the persons with infection are summarized in Table 1.

Overall, 98% of the persons with infection were gay or bisexual men, and 75% were White. The median age was 38 years. A total of 41% of the persons were living with HIV infection, and in the vast majority of these persons, HIV infection was well controlled; 96% of those with HIV infection were taking ART, and in 95% the HIV viral load was less than 50 copies per milliliter (Table 2). Preexposure prophylaxis had been used in the month before presentation in 57% of the

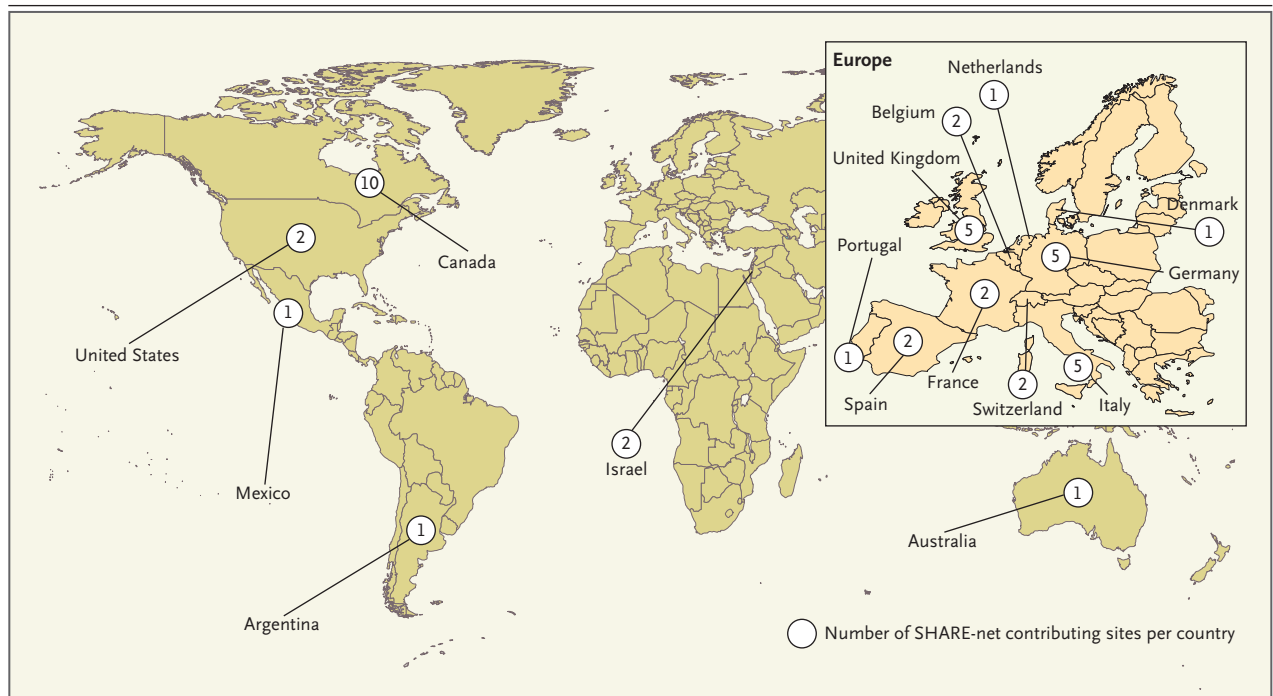


Figure 1. Global Distribution of SHARE-net Contributing Sites.

Among the 528 persons with monkeypox virus infection reported by these sites and included in the case series, 84 (16%) were in the Americas and 444 (84%) were in Europe, Israel, or Australia.

Characteristic	All Persons (N=528)
Median age (range) — yr	38 (18–68)
Sex or gender — no. (%)	
Male	527 (>99)
Female	0
Trans or nonbinary	1 (<1)
Sexual orientation — no. (%)†	
Heterosexual	9 (2)
Homosexual	509 (96)
Bisexual	10 (2)
Race or ethnic group — no. (%)‡	
White	398 (75)
Black	25 (5)
Mixed race	19 (4)
Latinx	66 (12)
Other or unknown	20 (4)
HIV positive — no. (%)	218 (41)
HIV negative or status unknown — no. (%)	310 (59)
Use of preexposure prophylaxis against HIV — no./total no. (%)	176/310 (57)
Foreign travel in month before diagnosis — no. (%)‡	147 (28)
Continent of travel — no./total no. (%)	
Europe	132/147 (90)
North America	9/147 (6)
Australasia	0/147
Africa and Middle East	2/147 (1)
Central and South America	2/147 (1)
Not stated	2/147 (1)
Known to have undergone STI screening — no. (%)	377 (71)
Microbiologically confirmed concomitant STI present — no./total no. screened (%)	109/377 (29)
Gonorrhea	32/377 (8)
Chlamydia	20/377 (5)
Syphilis	33/377 (9)
Herpes simplex virus infection	3/377 (1)
Lymphogranuloma venereum	2/377 (1)
Chlamydia and gonorrhea	5/377 (1)
Other or not stated	14/377 (4)
HIV test taken — no./total no. with previously unknown or negative HIV status (%)	122/310 (39)
New HIV infection diagnosis — no./total no. (%)	3/122 (2)
Sexual history not known — no./total no. (%)	122/528 (23)
Median no. of sex partners in previous 3 months (IQR)	5 (3–15)
“Chemsex” reported in the previous month — no. (%)	106 (20)
Reported attendance at a sex-on-site event in the previous month — no. (%)	169 (32)
Known hepatitis infection — no. (%)	
Hepatitis B virus surface antigen positive	6 (1)
Hepatitis C virus antibody positive	30 (6)
Hepatitis C virus RNA positive	8 (2)
Reported history of smallpox vaccination — no. (%)	49 (9)

* Percentages may not total 100 because of rounding. HIV denotes human immunodeficiency virus, IQR interquartile range, and STI sexually transmitted infection.

† Sexual orientation and race or ethnic group were reported by the persons.

‡ Travel from the country of residence in the month before the positive monkeypox virus polymerase-chain-reaction (PCR) result is shown.

persons who were not known to have HIV infection.

CLINICAL FINDINGS

The characteristics of monkeypox in this case series are summarized in Table 3. Skin lesions were noted in 95% of the persons (Fig. 2). The most common anatomical sites were the anogenital area (73%); the trunk, arms, or legs (55%); the face (25%); and the palms and soles (10%). A wide spectrum of skin lesions was described (see the clinical image Web library), including macular, pustular, vesicular, and crusted lesions, and lesions in multiple phases were present simultaneously. Among persons with skin lesions, 58% had lesions that were described as vesiculopustular. The number of lesions varied widely, with most persons having fewer than 10 lesions. A total of 54 persons presented with only a single genital ulcer, which highlights the potential for misdiagnosis as a different STI. Mucosal lesions were reported in 41% of the persons. Involvement of the anorectal mucosa was reported as the presenting symptom in 61 persons; this involvement was associated with anorectal pain, proctitis, tenesmus, or diarrhea (or a combination of these symptoms). Oropharyngeal symptoms were reported as the initial symptoms in 26 persons; these symptoms included pharyngitis, odynophagia, epiglottitis, and oral or tonsillar lesions. In 3 persons, conjunctival mucosa lesions were among the presenting symptoms. Common systemic features during the course of the illness included fever (in 62%), lethargy (41%), myalgia (31%), and headache (27%), symptoms that frequently preceded a generalized rash; lymphadenopathy was also common (56%).

The initial presenting feature and the sequence of subsequent cutaneous and systemic features (captured as free text) showed considerable variation. The most common presentation was an initial skin lesion or lesions, primarily in the anogenital area, body (trunk or limbs), or face (or a combination of these locations), with the number of lesions increasing over time and with or without systemic features (see the series of timelines in the clinical image Web library). Because of the observational nature of this case series, the variability in the time of presentation, and the reliance on clinical records, a clear chronology of potential exposure and symptoms was available for only 30 persons. Of these 30 persons, 23 had a clearly defined exposure event,

Table 2. Demographic and Clinical Characteristics of Persons with HIV Infection in the Case Series.*

Characteristic	Persons with HIV Infection (N=218)
Median age (range) — yr	39 (21–62)
Male sex — no. (%)	218 (100)
Sexual orientation — no. (%)	
Homosexual	212 (97)
Heterosexual	2 (1)
Bisexual	4 (2)
Median CD4 cell count (IQR) — cells/mm ³	680 (513–861)
Missing CD4 cell-count data — no. (%)	33 (15)
HIV viral load — no./total no. with data (%)	
<50 copies/ml	180/190 (95)
<200 copies/ml	185/190 (97)
Missing HIV viral load data — no. (%)	28 (13)
Known to be taking ART — no. (%)	210 (96)
ART regimen among those taking ART	
Backbone — no./total no. (%)	
Tenofovir-based three-drug regimen	102/210 (49)
Abacavir-based three-drug regimen	20/210 (10)
Zidovudine-based three-drug regimen	2/210 (1)
Two-drug regimen	48/210 (23)
Missing or unknown	38/210 (18)
Third agent — no./total no. (%)†	
Integrase inhibitor	129/210 (61)
NNRTI	31/210 (15)
bPI	11/210 (5)
Missing or unknown	39/210 (19)

* ART denotes antiretroviral therapy, bPI boosted protease inhibitor, and NNRTI nonnucleoside reverse-transcriptase inhibitor.

† Percentages were calculated with the total number of persons taking three-drug regimens (or two-drug regimens with integrase inhibitors included as a third agent) used as the denominator.

with a median time from exposure to the development of symptoms of 7 days (range, 3 to 20). Lesions with prodrome occurred in 17 of the 30 persons; however, isolated anogenital or oral lesions were also observed (13 persons). The median time from the onset of symptoms to the first positive PCR result was 5 days (range, 2 to 20), and the median time from the development of the first skin lesion to the development of additional skin lesions was 5 days (range, 2 to 11) (see the clinical image Web library). In persons for whom data on follow-up PCR testing were available, the latest time point at which a lesion

Characteristic	All Persons (N = 528)
Medical setting of presentation — no. (%)	
Sexual health clinic	120 (23)
Emergency department	106 (20)
Primary care	20 (4)
Dermatology clinic	38 (7)
HIV clinic	154 (29)
Other hospital clinic	30 (6)
Private clinics or other	60 (11)
Suspected route of transmission — no. (%)	
Sexual close contact	504 (95)
Nonsexual close contact	4 (1)
Other or unknown	17 (3)
Household contact	3 (1)
Contact with person known to have monkeypox — no. (%)	135 (26)
Reported clinical features — no. (%)	
Rash or skin lesions	500 (95)
Fever	330 (62)
Lymphadenopathy	295 (56)
Pharyngitis	113 (21)
Headache	145 (27)
Lethargy or exhaustion	216 (41)
Myalgia	165 (31)
Low mood	54 (10)
Proctitis or anorectal pain	75 (14)
Site of positive monkeypox viral PCR — no. (%)[†]	
Skin or anogenital lesion	512 (97)
Nose or throat swab	138 (26)
Blood	35 (7)
Urine	14 (3)
Semen	29 (5)
Site of skin lesions — no. (%)[‡]	
Anogenital area	383 (73)
Face	134 (25)
Trunk or limbs	292 (55)
Palms or soles	51 (10)
Description of rash — no./total no. with rash reported (%)	
Vesiculopustular	291/500 (58)
Macular	19/500 (4)
Single ulcer	54/500 (11)
Multiple ulcers	95/500 (19)
Other	41/500 (8)
No rash	28

Table 3. (Continued)	
Characteristic	All Persons (N = 528)
No. of skin lesions — no. (%)	
<5	207 (39)
5–10	131 (25)
11–20	112 (21)
>20	56 (11)
No lesions or missing data	22 (4)
Mucosal lesions present — no. (%)	217 (41)
Site of mucosal lesions — no./total no. (%)	
Anogenital only	148/217 (68)
Oropharyngeal only	50/217 (23)
Anogenital and oral	16/217 (7)
Nasal and eye	3/217 (1)
Medical care setting — no. (%)	
Inpatient	70 (13)
Outpatient	458 (87)
Received monkeypox-specific treatment — no. (%)	25 (5)
Treatment used — no. (%)	
Cidofovir	12 (2)
Tecovirimat	8 (2)
Vaccinia immune globulin	1 (<1)
Other	2 (<1)

* Percentages may not total 100 because of rounding.

† Some persons underwent testing from multiple sites, and not all sites were tested for all persons.

‡ More than one site per person may have been reported.

remained positive was 21 days after symptom onset.

The clinical presentation was similar among persons with HIV infection and those without HIV infection. The clinical characteristics of the persons with HIV infection are shown in Table 2. Concomitant STIs were reported in 109 of the 377 persons (29%) who were tested, with gonorrhea, chlamydia, and syphilis found in 8%, 5%, and 9%, respectively, of the those who underwent testing.

TRANSMISSION

The suspected means of monkeypox virus transmission as reported by the clinician was sexual close contact in 95% of the persons. It was not possible to confirm sexual transmission. A sexual history was recorded in 406 of 528 persons; among these 406 persons, the median number of sex

partners in the previous 3 months was 5 partners, 147 (28%) reported travel abroad in the month before diagnosis, and 103 (20%) had attended large gatherings (>30 persons), such as Pride events. Overall, 169 (32%) were known to have visited sex-on-site venues within the previous month, and 106 (20%) reported engaging in “chemsex” (i.e., sex associated with drugs such as mephedrone and crystal methamphetamine) in the same period.

A total of 70 persons (13%) were admitted to a hospital. The most common reasons for admission were pain management (21 persons), mostly for severe anorectal pain, and treatment of soft-tissue superinfection (18). Other reasons included severe pharyngitis limiting oral intake (5 persons), treatment of eye lesions (2), acute kidney injury (2), myocarditis (2), and infection-control purposes (13). There was no difference

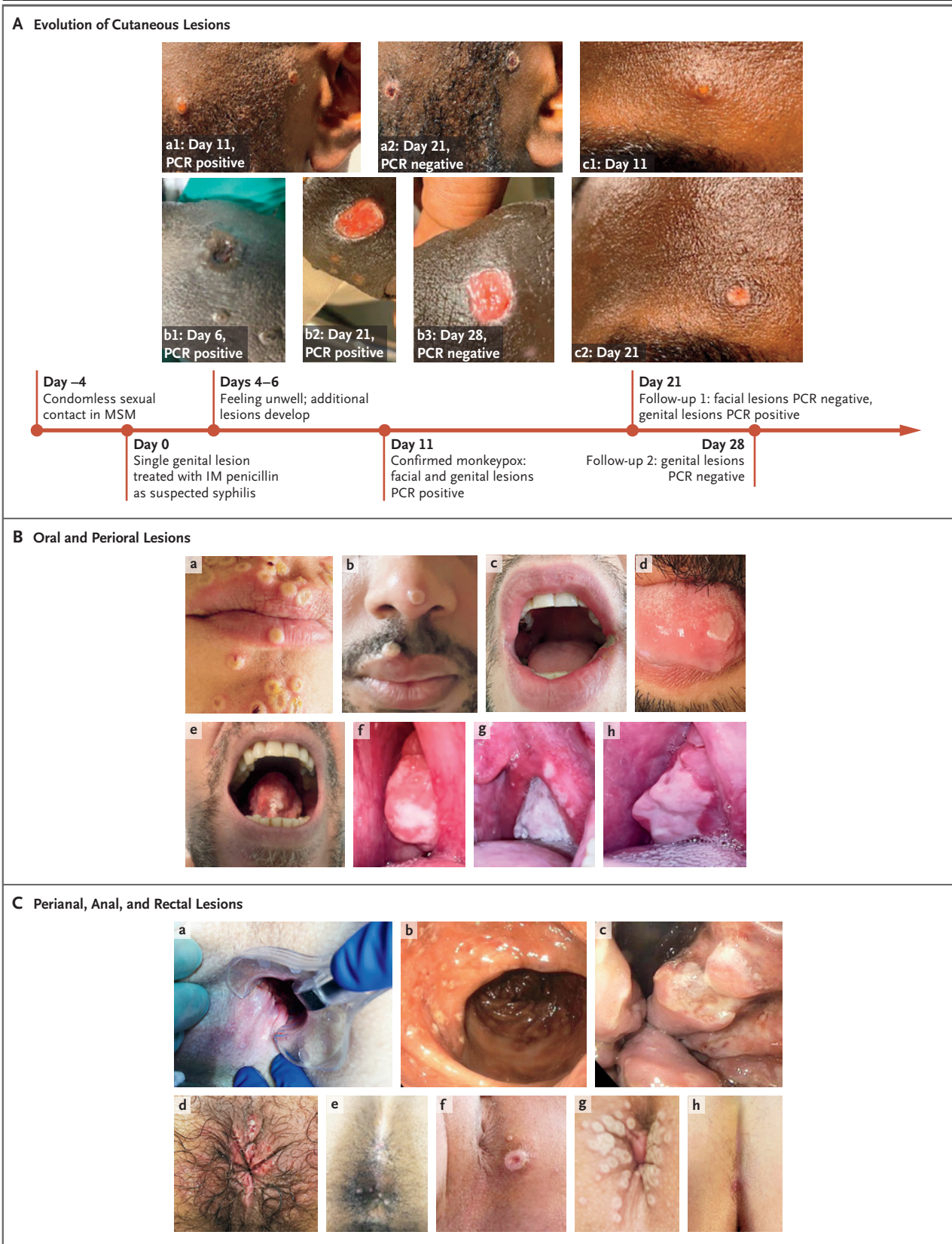


Figure 2 (facing page). Lesions in Persons with Confirmed Human Monkeypox Virus Infection.

Panel A shows the evolution of cutaneous lesions in a person with monkeypox; images a1 and a2 show facial lesions, images b1 through b3 show a penile lesion, and images c1 and c2 show a lesion on the forehead. The polymerase-chain-reaction (PCR) status is indicated if available. IM denotes intramuscular, and MSM man who has sex with men. Panel B shows oral and perioral lesions (image a, perioral umbilicated lesions; image b, perioral vesicular lesion on day 8, PCR positive; image c, ulcer on the left corner of the mouth on day 7, PCR positive; image d, tongue ulcer; image e, tongue lesion on day 5, PCR positive; and images f, g, and h, pharyngeal lesions on day 0, 3, and 21, respectively, PCR positive on day 0 and 3 and negative on day 21). Panel C shows perianal, anal, and rectal lesions (image a, anal and perianal lesions on day 6, PCR positive; images b and c, rectal and anal lesions in a single person, PCR positive; image d, perianal ulcers, PCR positive; image e, anal lesions; image f, umbilicated perianal lesion on day 3, PCR positive; image g, umbilicated perianal lesions on day 3, PCR positive; and image h, perianal ulcer on day 2, PCR positive).

in the frequency of admission according to HIV status. Three new cases of HIV infection were identified.

Two types of serious complications were reported: one case of epiglottitis and two cases of myocarditis. The epiglottitis occurred in a person with HIV infection who had a CD4 cell count of less than 200 per cubic millimeter; the person was treated with tecovirimat and recovered completely. The myocarditis cases were self-limiting (<7 days) and resolved without antiviral therapy. One occurred in a person with HIV infection who had a CD4 cell count of 780 per cubic millimeter, and one occurred in a person without HIV infection. No deaths were reported.

In total, 5% of the 528 persons received monkeypox-specific treatment. The drugs administered included intravenous or topical cidofovir (in 2% of persons), tecovirimat (2%), and vaccinia immune globulin (<1%).

DIAGNOSIS

The health setting of initial presentation reflected referral patterns and included sexual health or HIV clinics, emergency departments, and dermatology clinics and, less commonly, primary care. A positive PCR result was most commonly obtained from skin or anogenital lesions (97%); other sites were less frequently sampled. The report-

ed percentages of positive PCR results were 26% for nasopharyngeal specimens, 3% for urine specimens, and 7% for blood specimens. Semen was tested in 32 persons from five clinical sites and was PCR positive in 29 persons (4 of these instances have previously been reported¹⁹) (Table 4).

DISCUSSION

We describe a human monkeypox case series that includes 528 infections from four WHO regions (Europe, Americas, Western Pacific, and Eastern Mediterranean) and 16 countries reported over a 2-month period. Sexual activity, largely among gay or bisexual men, was by far the most frequently suspected route of transmission. The strong likelihood of sexual transmission was supported by the findings of primary genital, anal, and oral mucosal lesions, which may represent the inoculation site. Monkeypox virus DNA that was detectable by PCR in seminal fluid in 29 of the 32 cases in which seminal fluid was tested further supports this hypothesis. However, whether semen is capable of transmitting infection remains to be investigated, since it is unknown whether the viral DNA detected in these specimens was replication competent. Reports of clusters associated with sex parties or saunas further underscore the potential role of sexual contact as a promoter of transmission. International travel and attendance at large gatherings linked to sex-on-site activities may explain the global spread of monkeypox infections amplified through sexual networks.

The clinical presentation we describe has some distinct features not included in the internationally accepted case definitions.²⁰ Although these definitions recently expanded to include gay or bisexual men and other men who have sex with men as a risk group, they do not specifically highlight mucosal or rectal presentations, nor do they caution about the possibility of initial single-lesion manifestations. Existing definitions do recommend consideration of monkeypox in the context of any “unusual” rash but do not cover the full range of possible manifestations. Solitary genital skin lesions and lesions involving the palms and soles may easily lead to misdiagnosis as syphilis and other STIs, which may in turn delay detection. Concomitant laboratory-confirmed STIs were also reported in 29% of the persons tested. Consequently, we recom-

Table 4. Characteristics of 32 Persons with Monkeypox According to Presence or Absence of Viral DNA in Seminal Fluid on PCR.*

Seminal Fluid PCR Result and Person No.	Sexual Orientation	No. of Sex Partners in Past 3 Mo	Concomitant STI (Site)	HIV Status	Presenting Symptoms†	Rash	Location of Skin or Mucosal Lesions (No. of Lesions)	PCR Positivity for Monkeypox Virus
Positive								Skin Lesion Throat Swab
1	Homosexual	<5	None	Positive	1, 2, 3, 5, 6	MU	Genitals and face (<5)	Yes Yes
2	Bisexual	>20	None	Negative	1, 2, 4, 5, 6	VP	Genitals, trunk, limbs, and lip (>20)	Yes No
3	Homosexual	11 to 20	None	Positive	1, 2, 3, 4, 5, 6	VP	Genitals, palms, soles, rectum, mouth, and tongue (11–20)	Yes Yes
4	Homosexual	11 to 20	Chlamydia (rectum)	Negative	1, 2, 3, 4, 5	VP	Perianal area, rectum, penis, face, head, arm, and mouth (11–20)	Yes Yes
5	Homosexual	<5	None	Negative	1, 5	MU	Trunk and limbs (<5)	Yes No
6	Homosexual	>10	Gonorrhea (penis)	Positive	1, 5	VP	Perianal area, trunk, limbs, and tongue (>20)	Yes ND
7	Homosexual	>10	Unknown	Positive	5	VP	Perianal area, trunk, and limbs (11–20)	Yes Yes
8	Homosexual	>10	Unknown	Negative	1, 5	VP	Perianal area, trunk, limbs, and tongue (>20)	Yes ND
9	Homosexual	>10	Syphilis	Positive	5	VP	Genitals, trunk, and limbs (>20)	Yes Yes
10	Bisexual	3	Unknown	Negative	1, 5	VP	Perianal area, trunk, limbs, eyelid, and nasal mucosa (<5)	Yes No
11	Homosexual	<10	Unknown	Positive	None	VP	Penis, groin, and arms (<5)	Yes Yes
12	Homosexual	>10	Unknown	Positive	1	VP	Perianal area, penis, scrotum, and hand (<5)	Yes Yes
13	Homosexual	<10	None	Negative	1, 6	VP	Perianal area, wrist, and chest (11–20)	Yes Yes
14	Homosexual	<10	None	Negative	1, 5	VP	Penis, chest, and arms (11–20)	Yes Yes
15	Homosexual	<10	Unknown	Negative	1, 3, 6	VP	Penis, lip, face, and arm (11–20)	Yes Yes
16	Homosexual	<10	Syphilis	Positive	5, 6	VP	Penis, scrotum, arms, and wrist (11–20)	Yes Yes
17	Homosexual	1	Unknown	Negative	None	VP	Face (<5)	Yes Yes
18	Homosexual	1	Unknown	Positive	None	VP	Face (<5)	No Yes

19	Homosexual	<10	None	Positive	1	MU	Trunk and limbs (<5)	ND	Yes
20	Homosexual	2	Syphilis	Positive	1, 5	VP	Genitals (11–20)	Yes	Yes
21	Homosexual	<10	Unknown	Positive	1	VP	Arm, thigh, buttocks, and face (5–10)	Yes	Yes
22	Homosexual	Unknown	None	Negative	1, 3, 5	VP	Perianal area, penis, palms, soles, trunk, and limbs (11–20)	Yes	No
23	Homosexual	Unknown	None	Positive	1, 2, 3, 4, 5, 6	VP	Face, trunk, arms, and tonsil (5–10)	Yes	Yes
24	Homosexual	Unknown	Unknown	Negative	1, 4, 5	VP	Perianal area, rectum, penis, head, face, hand, and soles (5–10)	No	No
25	Homosexual	Unknown	None	Negative	1	MU	Perianal area (<5)	No	No
26	Homosexual	Unknown	None	Positive	1, 3, 4, 5, 6	VP	Perianal area (5–10)	No	No
27	Homosexual	Unknown	Unknown	Negative	1, 2, 3, 5, 6	Ma	Perianal area, rectum, penis, face, palm, and soles (>20)	No	No
28	Homosexual	Unknown	None	Positive	1, 2, 4, 5	Ma	Perianal area, rectum, penis, and face (11–20)	No	Yes
29	Homosexual	Unknown	Unknown	Negative	5	VP	Rectum, trunk, limbs, face, palms, soles, pharynx, and mouth (5–10)	No	No
Negative									
30	Homosexual	<10	None	Positive	1, 2, 3	VP	Penis and perianal area (5–10)	Yes	Yes
31	Homosexual	2	Unknown	Positive	1, 4, 5, 6	VP	Genitals (5–10)	ND	ND
32	Homosexual	3	Unknown	Positive	1, 3, 4	VP	Trunk and limbs (5–10)	No	Yes

* Ma denotes macular, MU multiple ulcers, ND not done, and VP vesiculopustular.

† Presenting symptoms are indicated as follows: 1, fever; 2, lethargy or exhaustion; 3, headache; 4, sore throat or pharyngitis; 5, lymphadenopathy; and 6, myalgia.

mend consideration of monkeypox in at-risk persons presenting with traditional STI symptoms.

In our series, the diagnosis of monkeypox was most commonly confirmed from swab specimens taken from skin or genital lesions, with throat or nasopharyngeal swab specimens and blood less commonly tested. Anal or rectal swabs should be considered for those presenting with anal pain or proctitis.

Clinical outcomes in this case series were reassuring. Most cases were mild and self-limited, and there were no deaths. Although 13% of the persons were admitted to a hospital, no serious complications were reported in the majority of those admitted. Common reasons for admission were pain and bacterial superinfection. However, rare serious complications (myocarditis and epiglottitis) were observed, and therefore the full spectrum of the disease and complications needs further study, particularly over the long term, given the short duration of our follow-up. The clinical presentation and severity of monkeypox appeared similar among persons with or without HIV infection, but in almost all those in our series who had HIV infection, HIV was well controlled, with a median CD4 cell count of 680 cells per cubic millimeter.

A small percentage of persons (5%) received antiviral therapy, most often with cidofovir or tecovirimat. Data on the effectiveness of these compounds in humans are limited, although studies in animals and case reports suggest that they may be active.²¹ In this case series, 56 persons were older than 50 years of age, and overall, 9% reported having previously received a smallpox vaccination, so we cannot comment on its effect.

Health care professionals need to be educated to recognize and manage cases of monkeypox. Targeted health promotion that sensitively supports enhanced testing and education in populations at risk is needed. Involving communities from the outset in shaping the implementation of public health interventions is essential to ensure that they are appropriate and nonstigmatizing and to avoid messaging that will drive the outbreak underground. The duration of potential infectious viral shedding after lesions have cleared remains unclear. UKHSA guidelines have advised condom use for 8 weeks after infection, but the potential duration and infectiousness of viral shedding in semen requires study. The potential

role of vaccines in preexposure prophylaxis also requires study; vaccines are currently being offered to persons who are at high risk for infection in the United Kingdom, New York City, and Canada.

Although the current outbreak is disproportionately affecting gay or bisexual men and other men who have sex with men, monkeypox is no more a “gay disease” than it is an “African disease.” It can affect anyone. We identified nine heterosexual men with monkeypox. We urge vigilance when examining unusual acute rashes in any person, especially when rashes are combined with systemic symptoms, to avoid missing diagnoses in heterosexual persons.

Several limitations of our study need to be highlighted. Our case series is an observational convenience case series in which infection was confirmed with various (locally approved) PCR platforms. Persons in this case series had symptoms that led them to seek medical care, which implies that persons who were asymptomatic, had milder symptoms, or were paucisymptomatic could have been missed. Established links between persons receiving preexposure HIV prophylaxis and sexual health clinics and between persons living with HIV infection and HIV clinics could have led to a referral bias, especially given the potential for early care seeking in these groups. Spread to other populations is anticipated, and vigilance is required. Symptoms were recorded from the time of presentation, and therefore early symptoms may have been underreported, limiting information on the incubation period.

Because viruses know no borders, the world needs to move cohesively and quickly to close knowledge gaps and to contain the outbreak. Without widely available treatment or prophylaxis, rapid case identification is vital to containment. As is common in clinical medicine, there is a diversity in how illnesses may manifest — and monkeypox is no different.

Disclosure forms provided by the authors are available at NEJM.org.

A data sharing statement provided by the authors is available with the full text of this article at NEJM.org.

We thank everyone who volunteered to be included in this descriptive case series and those who provided additional consent for their deidentified images to be shown, the many collaborating investigators for their dedication and their diligent review of the data provided, and Ms. Sadna Ullah of the SHARE Collaborative at Queen Mary University of London for administrative support.

APPENDIX

The authors' full names and academic degrees are as follows: John P. Thornhill, M.D., Ph.D., Sapha Barkati, M.D., Sharon Walmsley, M.D., Juergen Rockstroh, M.D., Andrea Antinori, M.D., Luke B. Harrison, M.D., Ph.D., Romain Palich, M.D., Ph.D., Achyuta Nori, M.D., Iain Reeves, M.D., Maximilian S. Habibi, M.D., Ph.D., Vanessa Apea, M.D., M.P.H., Christoph Boesecke, M.D., Linos Vandekerckhove, M.D., Ph.D., Michal Yakubovsky, M.D., Elena Sendagorta, M.D., Ph.D., Jose L. Blanco, M.D., Ph.D., Eric Florence, M.D., Ph.D., Davide Moschese, M.D., Fernando M. Maltez, M.D., Ph.D., Abraham Goorhuis, M.D., Ph.D., Valerie Pourcher, M.D., Ph.D., Pascal Migaud, M.D., Sebastian Noe, M.D., Claire Pintado, M.D., Fabrizio Maggi, M.D., Ph.D., Ann-Brit E. Hansen, M.D., Ph.D., Christian Hoffmann, M.D., Ph.D., Jezer I. Lezama, M.D., Ph.D., Cristina Mussini, M.D., AnnaMaria Cattelan, M.D., Keletso Makofane, M.P.H., Ph.D., Darrell Tan, M.D., Ph.D., Silvia Nozza, M.D., Ph.D., Johannes Nemeth, M.D., Marina B. Klein, M.D., and Chloe M. Orkin, M.D.

The authors' affiliations are as follows: the Blizard Institute and the SHARE Collaborative, Queen Mary University of London, and the Department of Infection and Immunity, Barts Health NHS Trust (J.P.T., V.A., C.M.O.), the Department of Genitourinary Medicine and Infectious Disease, Guys and St. Thomas' NHS Trust (A.N.), the Department of Sexual Health, Homerton University Hospital (I.R.), and the Clinical Infection Unit, St. George's University Hospitals NHS Foundation Trust (M.S.H.) — all in London; the Department of Medicine, Division of Infectious Diseases (S.B., L.B.H., M.B.K.), the J.D. MacLean Centre for Tropical Diseases (S.B.), the Research Institute of the McGill University Health Centre (S.B., M.B.K.), and the Chronic Viral Illness Service, Department of Medicine (M.B.K.), McGill University Health Centre, Montreal, and the Department of Medicine, University Health Network, University of Toronto (S.W.), the Division of Infectious Diseases and the MAP Centre for Urban Health Solutions, St. Michael's Hospital (D.T.), and the Department of Medicine, University of Toronto (D.T.), Toronto — all in Canada; University Hospital Bonn, Department of Medicine I, Bonn (J.R., C.B.), the Department of Infectious Diseases, St. Joseph Hospital, Berlin (P.M.), Medizinisches Versorgungszentrum (MVZ) München am Goetheplatz, Munich (S. Noe), and the Infektionsmedizinisches Centrum Hamburg (ICH) Study Center, Hamburg MVZ ICH Stadmitte, Hamburg (C.H.) — all in Germany; the National Institute for Infectious Diseases Lazzaro Spallanzani IRCCS, Rome (A.A., F.M.), the Division of Infectious Disease, Luigi Sacco Hospital, Azienda Socio-Sanitaria Territoriale Fatebenefratelli Sacco (D.M.), and the Department of Infectious and Tropical Diseases, IRCCS-Ospedale San Raffaele (S. Nozza), Milan, the Clinic of Infectious Diseases, University of Modena, Modena (C.M.), and the Infectious Diseases Division, Department of Medical Sciences, Azienda Ospedale Università, Padua (A.C.) — all in Italy; the Department of Infectious Diseases, Sorbonne University, Assistance Publique-Hôpitaux de Paris (AP-HP), Pitié-Salpêtrière Hospital (R.P., V.P.), and the Department of Infectious Diseases, Saint Louis Lariboisière Hospital, AP-HP, University of Paris Cité (C.P.), Paris, and the Department of Prevention and Community Health, Créteil Intercommunal Hospital, Créteil (C.P.) — all in France; the HIV Cure Research Center, Department of Internal Medicine and Pediatrics, Faculty of Medicine and Health Sciences, Ghent University and Ghent University Hospital, Ghent (L.V.), and the HIV/STI Clinic, Institute of Tropical Medicine, Antwerp (E.F.) — both in Belgium; the Sackler Faculty of Medicine, Tel Aviv University, and the Israel Department of Infectious Diseases and Infection Control, Tel Aviv Sourasky Medical Center, Tel Aviv, Israel (M.Y.); the Department of Dermatology, University Hospital La Paz, Centro de Investigación Biomédica en Red de Enfermedades Infecciosas (CIBERINFEC), Instituto de Investigación Hospital Universitario La Paz (E.S.), and CIBERINFEC, Instituto de Salud Carlos III (J.L.B.), Madrid, and the Infectious Diseases Service, Hospital Clinic-IDIBAPS (Instituto de Investigaciones Biomédicas August Pi i Sunyer), University of Barcelona, Barcelona (J.L.B.) — all in Spain; Hospital de Curry Cabral—Centro Hospitalar Universitário de Lisboa Central, Lisbon, Portugal (F.M.M.); Amsterdam University Medical Centers, University of Amsterdam, Amsterdam (A.G.); the Department of Infectious Diseases, University Hospital of Copenhagen, Hvidovre, Denmark (A.-B.E.H.); the Condesa Specialized Clinic, Mexico City (J.I.L.); the François-Xavier Bagnoud Center for Health and Human Rights at Harvard University, Boston (K.M.); and the Department of Infectious Diseases and Hospital Epidemiology, University Hospital Zurich, Zurich, Switzerland (J.N.).

REFERENCES

- Ladnyj ID, Ziegler P, Kima E. A human infection caused by monkeypox virus in Basankusu Territory, Democratic Republic of the Congo. *Bull World Health Organ* 1972;46:593-7.
- Human monkeypox — Kasai Oriental, Democratic Republic of Congo, February 1996–October 1997. *MMWR Morb Mortal Wkly Rep* 1997;46:1168-71.
- Durski KN, McCollum AM, Nakazawa Y, et al. Emergence of monkeypox — West and Central Africa, 1970–2017. *MMWR Morb Mortal Wkly Rep* 2018;67:306-10.
- Vaughan A, Aarons E, Astbury J, et al. Two cases of monkeypox imported to the United Kingdom, September 2018. *Euro Surveill* 2018;23:1800509.
- Vaughan A, Aarons E, Astbury J, et al. Human-to-human transmission of monkeypox virus, United Kingdom, October 2018. *Emerg Infect Dis* 2020;26:782-5.
- Erez N, Achdout H, Milrot E, et al. Diagnosis of imported monkeypox, Israel, 2018. *Emerg Infect Dis* 2019;25:980-3.
- Yong SEF, Ng OT, Ho ZJM, et al. Imported monkeypox, Singapore. *Emerg Infect Dis* 2020;26:1826-30.
- Yinka-Ogunleye A, Aruna O, Dalhat M, et al. Outbreak of human monkeypox in Nigeria in 2017-18: a clinical and epidemiological report. *Lancet Infect Dis* 2019;19:872-9.
- Bunge EM, Hoet B, Chen L, et al. The changing epidemiology of human monkeypox — a potential threat? A systematic review. *PLoS Negl Trop Dis* 2022;16(2):e0010141.
- Multi-country monkeypox outbreak: situation update. World Health Organization, June 17, 2022 (<https://www.who.int/emergencies/disease-outbreak-news/item/2022-DON393>).
- Multi-country monkeypox outbreak: situation update. World Health Organization, June 27, 2022 (<https://www.who.int/emergencies/disease-outbreak-news/item/2022-DON396>).
- Monkeypox: background information. UK Health Security Agency, 2018 (<https://www.gov.uk/guidance/monkeypox#transmission>).
- Mbala PK, Huggins JW, Riu-Rovira T, et al. Maternal and fetal outcomes among pregnant women with human monkeypox infection in the Democratic Republic of Congo. *J Infect Dis* 2017;216:824-8.
- Monkeypox. World Health Organization, May 19, 2022 (<https://www.who.int/news-room/fact-sheets/detail/monkeypox>).
- Ogoina D, Iroezindu M, James HI, et al. Clinical course and outcome of human monkeypox in Nigeria. *Clin Infect Dis* 2020;71(8):e210-e214.
- 2022 Monkeypox outbreak global map. World Health Organization, 2022 (<https://www.cdc.gov/poxvirus/monkeypox/response/2022/world-map.html>).
- O'Toole Á, Rambaut A. Initial observations about putative APOBEC3 deaminase editing driving short-term evolution of MPXV since 2017. 2022 (<https://>

- virological.org/t/initial-observations-about-putative-apobec3-deaminase-editing-driving-short-term-evolution-of-mpxv-since-2017/830).
18. Monkeypox: case definitions. UK Health Security Agency, 2022 (<https://www.gov.uk/guidance/monkeypox-case-definitions>).
19. Antinori A, Mazzotta V, Vita S, et al. Epidemiological, clinical and virological characteristics of four cases of monkeypox support transmission through sexual contact, Italy, May 2022. *Euro Surveill* 2022;27:2200421.
20. Monkeypox outbreak toolbox. World Health Organization, 2022 (<https://www.who.int/emergencies/outbreak-toolkit/disease-outbreak-toolboxes/monkeypox-outbreak-toolbox>).
21. Grosenbach DW, Honeychurch K, Rose EA, et al. Oral tecovirimat for the treatment of smallpox. *N Engl J Med* 2018;379:44-53.

Copyright © 2022 Massachusetts Medical Society.